x 8.4 mm) on the mandible at the symphysis, more on the left side than on the right, but overlapping the midline.

On the right radius at the distal end there is a slight green stain on the anterior surface of the bone (see Plate 27). This stain corresponds to a longitudinal cut mark which has green staining within the bone, and the cut mark has a shiny surface inside. The green stain also occurs on the anterior margin of the articular surface and the cut mark extends to that point. A possibility is that this represents the remains of a shroud pin which was actually inserted into the bone at the wrist. No green staining occurs on any of the adjacent carpals, though there is a very diffuse greenish-yellow stain on the lateral side of the first metacarpal.

f) *Stature*

Based on the formula for stature reconstruction for American White Males (Trotter 1970), using femoral and tibial length, this individual's stature was 174.2 +/- 2.99 cm (68.6 inches). Reconstruction of stature based on the other long bones (fibula, humerus, radius, and ulna) all have overlapping ranges with this estimate (see Table 11). Given the osteoporosis of the vertebral column and the advanced age of the individual, stature close to the time of death was probably somewhat shorter.

g) *Population Affinity*

This specimen is almost certainly from an individual of European ancestry. There seems to be a nasal sill and the zygomatic arches are retreating, both typically Caucasoid features. The interorbital region shows a frontal process which is angled away from the nasal bones as Gill and Gilbert (1990) argue is characteristic of Europeans. The form of the zygomaxillary suture seems to be of the "angled" form rather than the "curved" form. This form is more often characteristic of "Mongoloids" than of "Caucasoid" (Rhine 1990). The chin seems to have a bilateral projection as is often the case in Europeans (Gill 1986). On balance this individual has mostly "Caucasoid" features. Analysis of cranial metrics using discriminant functions (to distinguish between Whites and Blacks and Whites and Indians, in both cases using functions for males) from Giles and Elliot (1962) also classifies this individual as of European ancestry.

h) *Summary*

This was an elderly male individual with evidence of old age in the extensive antemortem tooth loss and extreme osteoarthritis throughout the skeleton and resulting "spondylosis deformans" in the vertebral column. He had no bony pathologies other than these age-related ones. He would have been about 68.6 inches (5 feet, 9 inches) tall during life (prior to the onset of bone loss) and was almost certainly of European ancestry.

2. FEATURE 9

a) *Skeletal Inventory and Condition*

In general the preservation and condition of this skeleton is excellent, with almost the entire skeleton preserved.

The cranium of this individual is complete and in excellent condition (see Plates 28 and 29). There is a crack extending from just posterior to the coronal suture on the right side, down the temporo-sphenoidal suture, through the right occipital condyle, across the foramen magnum, up the left temporo-occipital suture and into the lambdoidal suture. This crack caused the bones to spread apart slightly. The left occipital condyle has broken off. All maxillary teeth which were present at the time of death were preserved (LI^1 through LM^2 and RI^1 through LM^1). The mandible is

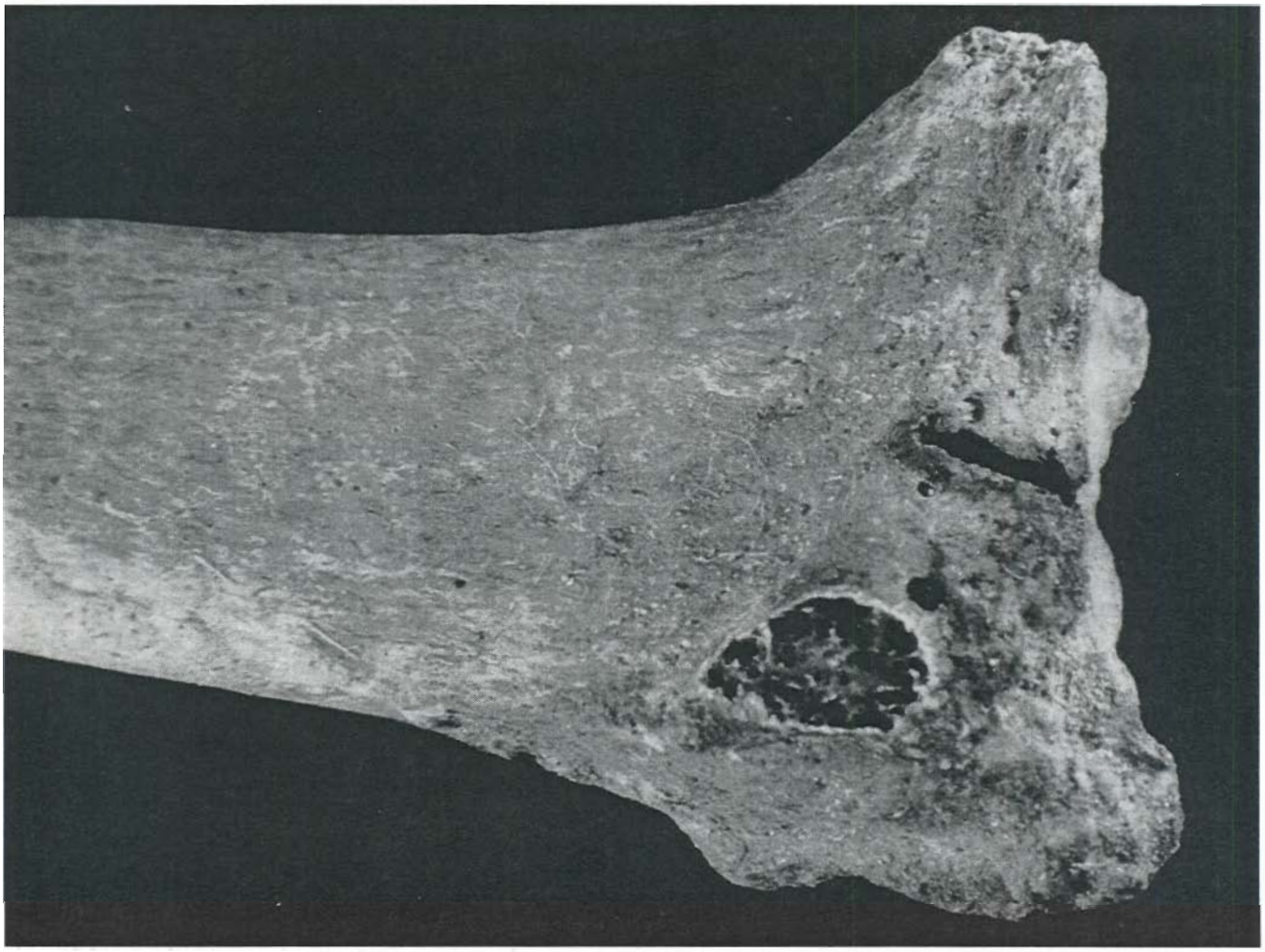

PLATE 27: The Anterior Surface of the Distal End of the Radius from the Individual from Feature 5.
Note the longitudinal cut mark which is associated with green staining.

PLATE 28: The Cranium from the Individual from Feature 9 in Lateral View.

This cranium is from a female, while the one from feature 5 is from a male. Note that this individual was more gracile, and lighter temporal lines and nuchal region than the individual from feature 5. Note Also, the presence of green staining on the left frontal near the temporal line.

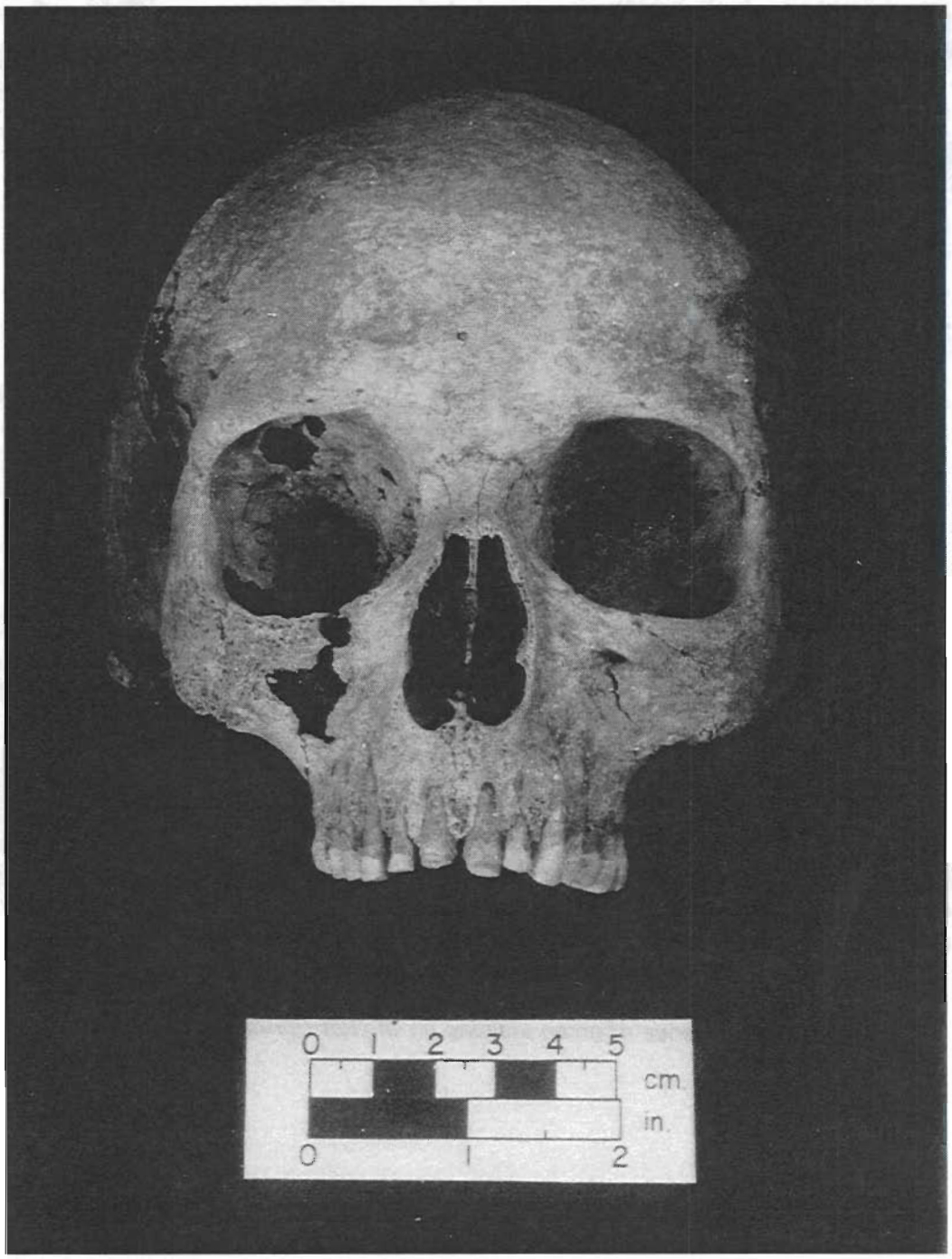

PLATE 29: The Cranium from the Individual from Feature 9 in Anterior View.

complete and in excellent condition also, with all teeth which were present at the time of death preserved.

The vertebral column is complete, with seven cervical, twelve thoracic, and five lumbar vertebrae, all with no postmortem damage.

The sacrum is present although the inferior (spongy) portion is damaged. Both innominates are present. In both cases they are complete with the exception of some destruction of the thin portion of the iliac blade (the right is slightly more complete than the left).

The manubrium is present in very poor condition and only fragments of the sternum were preserved. Ten left and ten right ribs were represented. The first ribs are complete; the remaining ribs are fragmentary.

Essentially all long bones of the lower limb are complete and in excellent condition, with some damage to the outer table of bone on the spongy areas of the diaphyses. The fibulae are in poor condition, though the major portions of the shaft are present. Both patellae are present in good condition.

The feet are well preserved with all tarsals and metatarsals present on both sides in good condition. The phalanges are represented by seven phalanges and six phalangeal fragments from the right side and two phalanges on the left.

The scapulae are both preserved although the areas of thin bone are not well preserved; in both cases the glenoid fossa, scapular spine, and coracoid process are all that remain. The clavicles are both present though the right is somewhat damaged on the inferior surface.

The humeri, ulnae, and radii are all present. The humeri are in good condition, with damage to the outer table of the spongy portions of both diaphyses. The ulnae are complete but with the distal ends deteriorated. The radii are present and are also in good condition, with some damage to the outer surfaces of the spongy portions of the bone. All of the carpals from both wrists are present in good condition. All ten metacarpals are present though again the ends are somewhat deteriorated in a manner similar to the long bones as described above. A total of eleven phalanges from the two hands are preserved.

b) *General Description and pathology*

1) Cranium

The cranium is extremely gracile (see Plates 28 and 29). Although there is a slight prominence at glabella there is very little supraorbital development medially over the central portion of the orbits, or laterally. Temporal lines are extremely light and the nuchal region is very smooth. Mastoid processes are very small.

The cranial sutures are fused and obliterated endocranially. Ectocranially, the sagittal and coronal sutures are well fused though still visible. The lambdoidal suture is open in several places, but this may be partly the result of the crack which has extended throughout the cranium (see above).

Maxillary and mandibular teeth are all worn moderately heavily (see Table 7). Several molars (LM^3, RM^2, RM^3, RM^1, RM^2) were lost antemortem. LM_1 and LM_2 were decayed and only portions of the roots remained (not included in Plate 30). Alveolar resorption on the maxilla proceeded to a point at which the bone is smooth and there is no evidence of the sockets remaining. The maxillary teeth which were present in the jaw at the time of death were free of carious lesions. On the lingual surface of LP^1 through LM^2 and RP^2 through RM^2 there is calculus at the cemento-

enamel junction. A band of **enamel hypoplasia** is visible on the upper LC. The mandible has evidence of a large abscess and resorption in the area of the alveolus where RM_1 and RM_2 had been. The RM_3 has a large carious (interproximal) lesion at the cemento-enamel junction on the mesial surface and another at the cemento-enamel junction on the distal surface. In addition, on the alveolus just lingual to the distal portion of RM_3, there is a bony nodule. The alveolus around this tooth has resorbed. On the left side, the roots of LM_1 and LM_2 are present, but the crowns are entirely decayed. In the area of the alveolus where LM_3 was lost, the bone is almost smoothed over, with some very small pits remaining on the surface of the bone.

Both the temporal and mandibular surfaces of the temporomandibular joints are very smooth and free of arthritis. The occipital condyle which is present is also smooth with no evidence of lipping. No evidence of bony pathology is visible on the cranium.

2) Vertebral Column

There are some very slight irregular bony growths on the articular surface of the atlas (first cervical vertebra) for the dens and on the corresponding surface of the axis (second cervical vertebra). The vertebral bodies of the remaining cervical vertebrae have very slight developments of marginal osteophytes with some macroporosity on the articular surfaces (see Plate 30).

The thoracic vertebrae are similar in having mild marginal osteophytic development, resulting in slight lipping which increases as one moves from the superior to the inferior vertebrae. The articular surfaces of the bodies have some slight porosity.

The lumbar vertebrae also have some marginal osteophytic development with slight lipping. This is greatest on the inferior articular surface of L5 in which there is moderate marginal osteophytic development on the lateral edges of the inferior articular surfaces. The superior and inferior articular facets on all the vertebrae are essentially free of any lipping.

3) Sacrum and Pelvis

There is moderate marginal osteophytic development on the superior articular surface of the sacrum. The surface of that joint has very fine porosity. The sacral surface of the sacroiliac joint has slightly more porosity.

The innominates are very small overall. The ischial tuberosities are gracile. The acetabula are small with very slight lipping on the margins. There is a very slight rough enedarea in the preauricular region, but no preauricular sulcus, nor is there any pitting on the dorsal surface of the left pubis (the right pubis does not preserve this region). The iliac surface of the sacroiliac joint has fine porosity. The pubic ramus is long. Traits which Phenice (1969) has shown to be excellent indicators of sex can be evaluated on the right, but not the left innominate. There appears to be a ventral arc on the right side. There is definitely a subpubic concavity and the medial aspect of the ischiopubic ramus is ridged. These are all features which are characteristic of females. In addition, the sciatic notches are wide and symmetrical.

4) Ribs, Manubrium, and Sternum

No evidence of pathology is visible on the fragmentary ribs, manubrium, or sternum.

5) Lower Limb

Femora are extremely gracile with light linea aspera and muscle markings. The fovea capitis on both sides has some slight osteophytic development. No other pathology is evident on the femora.



PLATE 30: The Second Through Seventh Cervical Vertebrae from the Individual from Feature 9 in Anterior View. *Superior is to the right in this picture. The projection at the top of the second cervical vertebra is the dens or odontoid process which articulates with a corresponding facet on the first vervical vertebra (the atlas).*

The tibiae are similarly extremely gracile and free of bony pathology, although the proximal articular surfaces are somewhat eroded, so that a complete evaluation of their margins is not possible. The distal articular surface of the right tibia has a very slight amount of lipping. No pathology is visible on the fragmentary fibulae.

The tarsals, metatarsals, and phalanges of the feet have no visible bony pathology, with the exception of very slight marginal lipping on a few articular facets.

6) Upper Limb

Scapulae are fragmentary, but areas which are present are free of pathology except for extremely small marginal osteophytes on glenoid fossa and a very mild degree of lipping. Clavicles are short and very gracile, with slight porosity on the articular surface of the manubrium.

Humeri, like the lower limb bones, are gracile and slender. The deltoid tuberosity is very poorly developed. The olecranon fossa is not perforated. There is an area on the lateral aspect of the left humerus which may be evidence of periostitis. The surface of the bone is somewhat eroded; beneath it the bone is much less compact (more spongy) than expected. A definitive diagnosis is difficult given the condition of the bone surface.

Ulnae are gracile. On both ulnae, the trochlear notch has a slight ridge of bone extending transversely across the joint surface. Joint surfaces are sufficiently eroded that it is impossible to evaluate their margins. Radii are in slightly poorer condition. There seems to be very slight lipping on the distal surface of the left radius.

The hands are in poor condition. No pathology is visible with the exception of slight lipping on the articular surfaces of some carpals.

c) *Sex*

Feature 9 is clearly female. This is based both on the pelvis (in which all Phenice characters, and the width of the sciatic notch, suggest that it is female) and the cranium (see above). The gracility of the postcranial skeleton is entirely consistent with this. Analysis of the cranial metrics by discriminant function from Giles and Elliot (1962) classifies this individual as female.

d) *Age*

Feature 9 is certainly a mature adult. All epiphyses were fused as was the **spheno-occipital synchondrosis**. All teeth were erupted and as indicated above, several were lost antemortem, probably many years before the individual died. The surface of the pubic symphysis is quite eroded, but is consistent with a mature adult. However, there is very little osteoarthritis or osteoporosis. This individual is certainly younger than Feature 5 (probably in the late 40s or early 50s at the time of death).

e) *Cultural Modifications*

There are two green stains on the skull. The larger and more intense stain is on the temporal line on the left frontal, and the smaller and much less intense one is on the corresponding point on the right frontal.

f) *Stature*

Based on the formula for stature reconstruction for American White Females (Trotter 1970), using femoral and tibial length, this individual's stature was 159.7 +/- 3.55 cm (62.9 inches).

Reconstructions of stature based on the individual bones, or on the humerus (the only other long bone in sufficiently good condition to measure), are within a very tightly clustered 1 cm of this estimate.

g) *Population Affinity*

This skull appears to be European. There is a nasal sill. The interorbital region shows a frontal process which is angled away from the nasal bones. The zygomatic arches are retreating (though less so than in Feature 5). The zygomaxillary suture is of the angled form, similar to that seen in Feature 5. Analysis of the cranial metrics using the Giles and Elliot (1962) discriminant functions for females classifies Feature 9 as White on the White/Indian discriminant function and just at the line between Whites and Negroes on the White/Negro discriminant function. This individual is almost certainly of European ancestry.

h) *Summary*

This individual was a mature, but not elderly, female. The only bony pathology present at the time of death was minor evidence of degenerative arthritis and dental decay, abscess, and loss. She was approximately 62.9 inches (5 feet, 3 inches) tall and of European ancestry.

3. FEATURE 15

a) *Skeletal Inventory and Condition*

Feature 15 was apparently disturbed by intrusive activity and much of the skeleton is missing.

The cranium and mandible are absent.

Four complete cervical vertebrae (probably C3, C4, C6, and C7) are present in excellent condition. In addition, fragments of C1 and C2 are preserved in poor condition. Fifteen lumbar and thoracic vertebrae are preserved. Three of them are certainly L3-L5, but the condition of the others makes it impossible to determine precisely which vertebrae are absent.

The sacrum is present though the inferior portion (below S2) is not preserved. Both innominates are present in fairly good condition. The left is complete with the exception of the anterior portion of the ilium and a small portion of ischiopubic ramus. The right is complete with the exceptions of the anterior portion of the ilium and the top portion of the pubis at the pubic symphysis.

The lower limbs are not preserved. However, there is a first cuneiform from a left foot, discovered out of place, which the excavators suggest may be associated with the skeletal material from Feature 15. Nothing about the bone contradicts this interpretation.

A small fragment of sternum is preserved in poor condition. In addition, a number of rib fragments are preserved (approximately eight from the right side and nine from the left side). In only five of these ribs (including one first rib) are the vertebral articulations present.

Both clavicles are present. On the right side, only the middle portion of the bone is preserved, with no articular ends; on the left side the bone is complete with the exception of the distal end. The scapulae are present; in both cases the glenoid fossa is present in good condition as well as a portion of the scapular spines and coracoid processes. The medial borders of both scapulae are absent. More of the right scapula is present than the left. Both humeri are present. The right one is complete and in excellent condition, with only some outer bone missing from the humeral head. The left humerus has both the proximal and distal portions quite eroded. Both ulnae are present. The right is in excellent condition; the left is in very poor condition, retaining only the shaft and a