ancestry, stature was estimated using sex-appropriate regressions derived from American White populations and provided in Trotter (1970). Estimates of stature based on all available long bones for each individual are given in Table 11.

B. DESCRIPTIONS OF INDIVIDUAL SKELETONS

1. FEATURE 5

a) *Skeletal Inventory and Condition*

The preservation and condition of this skeleton was excellent, and it is essentially complete. It is by far the best preserved skeleton in this sample.

The cranium and mandible are generally in excellent condition, though the face is broken off from the cranium, the posterior portion of the foramen magnum is broken, and the temporal bones are slightly loose from the rest of the skull (see Plates 18 and 19). Some of the cranial measurements taken on this individual are therefore estimates (estimated measurements are indicated by parentheses in the tables). An indication of the quality of preservation is shown by the fact that both styloid processes are preserved. In addition, portions of the hyoid are present as well as a great deal of the ossified hyoid cartilage.

The vertebral column is extremely well preserved. All seven cervical vertebrae are present, in excellent condition, as well as all twelve thoracic and all five lumbar vertebrae. The pelvis is completely preserved with the exception of the anterior portion of the ilium, pubis, and ischium from the left side; thus, the pubis is virtually absent, with only a small portion remaining close to the acetabular border. There are fresh breaks indicating that this damage was quite recent. The left superior pubic ramus and portion of the ischium are present but in very poor, crumbling condition. The right side of the anterior portion of the pelvis is complete. Only the superior portion of the sacrum is preserved (S1-2, including the iliac articular surface).

The manubrium, sternum, and ribs are in poor condition. The sternum consists of only very small fragments. Identifiable ribs were as follows: both first ribs, the right second rib, and portions of the right fifth through eighth ribs were preserved. Other ribs are fragmentary and it was impossible to identify them individually.

TABLE 6

SUMMARY INFORMATION ON AGE AND SEX FOR EACH BURIAL

FEATURE NUMBER	SEX	AGE
5	male	elderly (50-60s)
9	female	middle-aged (40s)
15	female	middle-aged (late 20-40s)
29	indeterminate	4-5 years
30	indeterminate	birth-6 months
36	female	middle-aged (30-40s)
38	male	middle-aged (30-40s)
39	male	middle-aged (30-40s)
40	female	elderly (50-60s)

TABLE 7

DENTAL ATTRITION FOR INDIVIDUALS FROM SITE 7S-F-68

TOOTH	FEATURE NUMBER				
	5	9	38	39	40
			MAXILLARY TEETH		
RI1	.	6	.	6	.
RI2	.	6	.	.	.
RC	.	5	.	5	.
RP1	.	6	.	.	.
RP2	.	6	.	.	.
RM1	.	.	3	.	.
RM2	.	.	3	3	.
RM3	.	6	.	3	.
LI1	.	6	.	6	5
LI2	.	6	.	5	.
LC	.	4	.	.	5
LP1	.	5	.	.	6
LP2	.	4	.	.	.
LM1	3	.	.	.	.
LM2	.	.	.	4	.
LM3	4	.	.	4	3
			MANDIBULAR TEETH		
RI1	.	5	3	4	.
RI2	.	5	3	4	.
RC	.	4	4	3	.
RP1	.	5	.	3	.
RP2	.	4	.	2	.
RM1	.	5	.	.	.
RM2	.	3	5	.	.
RM3	.	.	.	3	.
LI1	.	6	3	4	.
LI2	.	6	3	4	.
LC	.	.	3	3	.
LP1	.	5	4	2	.
LP2	.	4	4	2	.
LM1	.	5	.	.	.
LM2	.	.	5	.	.
LM3	.	.	.	3	.

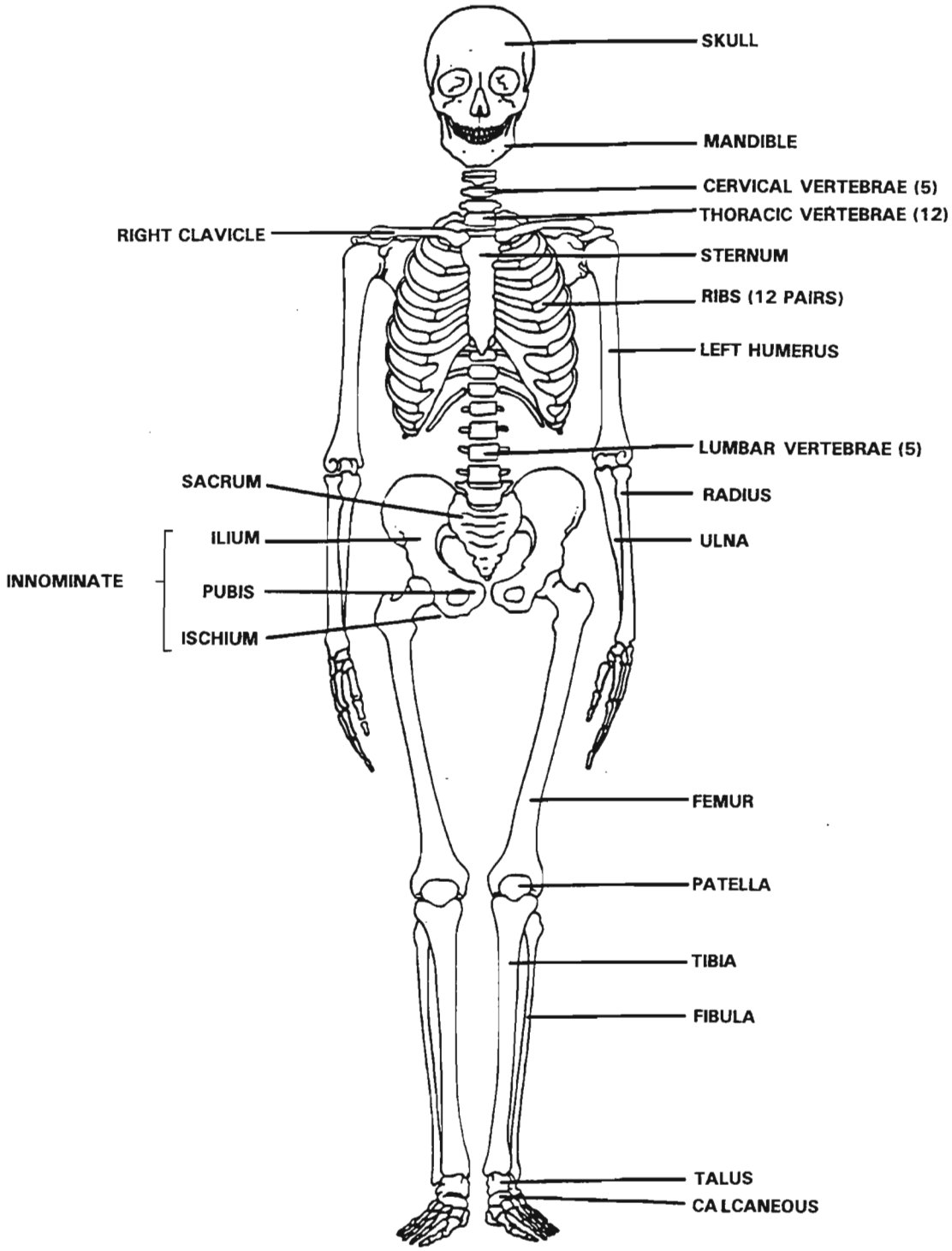

FIGURE 14: Principal Bones of the Human Skeleton *Source: Ubelaker 1978*

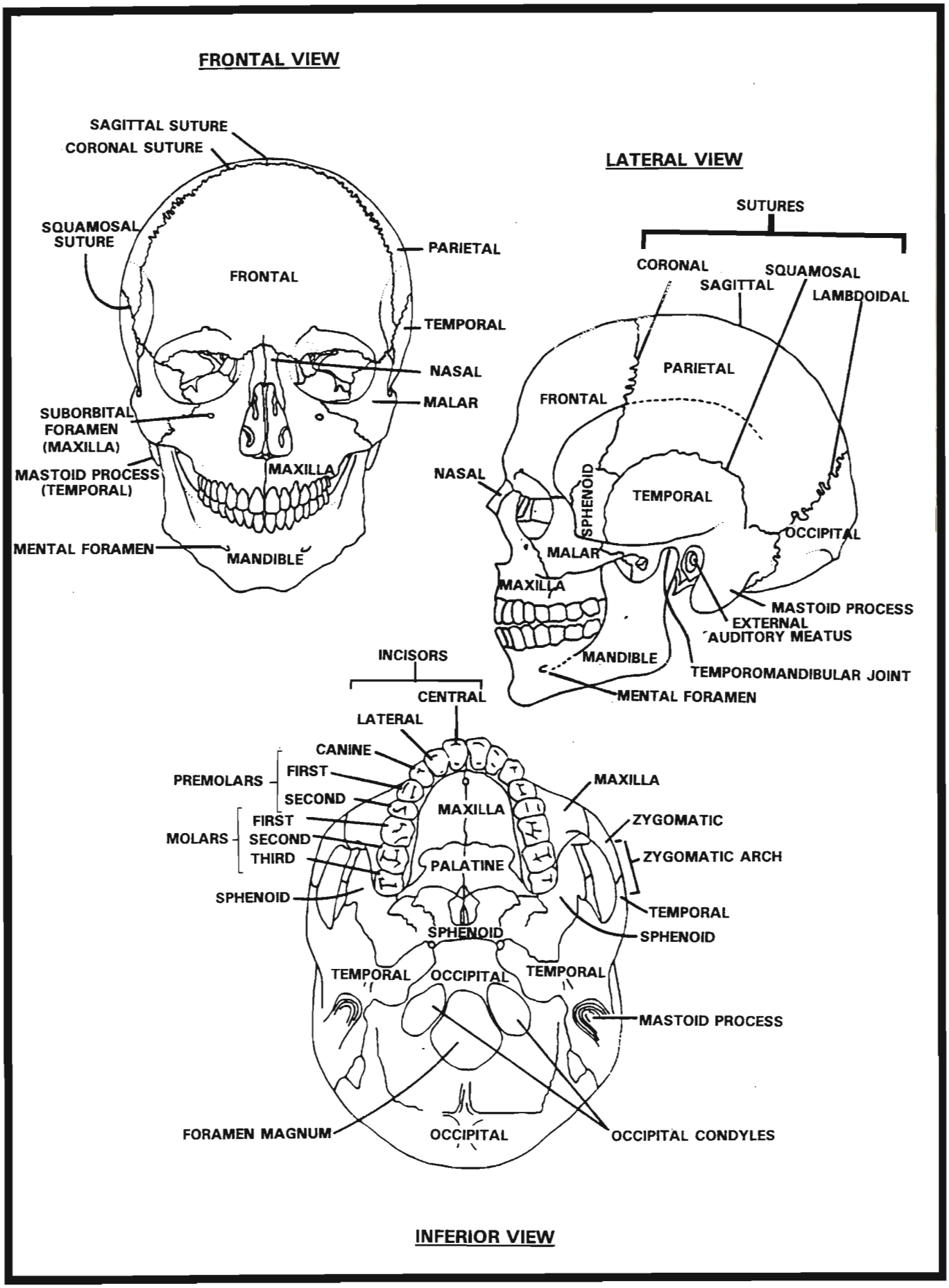

FIGURE 15: Bones and Features of the Human Skull *Source: Ubelaker 1978*

TABLE 8

DENTAL METRICS (in mm) FOR INDIVIDUALS FROM SITE 7S-F-68

TOOTH		BURIAL FEATURE NUMBER					
		5	9	29	36	38	39
			MAXILLARY TEETH				
RI1	MD	.	7.4	.	7.6	.	8.6
	BL	.	7.4	.	6.2	.	8.3
RI2	MD	.	4.4	.	.	.	6.8
	BL	.	5.9	.	.	.	6.6
RC	MD	5.8	5.6	.	.	.	7.8
	BL	8.4	7.1	.	.	.	9.0
RP1	MD	.	5.8	.	.	.	.
	BL	.	8.4	.	.	.	.
RP2	MD	.	5.4	.	.	.	.
	BL	.	8.6	.	.	.	.
RM1	MD	10.1	9.7	.	.	9.6	.
	BL	11.4	10.2	10.9	.	12.9	.
RM2	MD	.	.	.	.	9.0	9.5
	BL	.	.	.	.	13.7	10.8
RM3	MD	8.4	.	.	.	.	7.3
	BL	10.7	.	.	.	.	10.6
LI1	MD	.	6.4	.	(8.6)	.	8.3
	BL	.	7.5	.	6.9	.	8.4
LI2	MD	.	5.5	.	.	.	6.9
	BL	.	5.9	.	.	.	6.5
LC	MD	.	6.0	.	7.3	.	.
	BL	.	7.5	.	8.2	.	.
LP1	MD	.	5.2	.	.	.	.
	BL	.	8.1	.	.	.	.
LP2	MD	.	5.5	.	.	.	.
	BL	.	8.8	.	.	.	.
LM1	MD	.	9.1	10.1	.	.	.
	BL	.	10.4	10.7	.	.	.
LM2	MD	.	8.2	.	.	.	.
	BL	.	10.1	.	.	.	.
LM3	MD	.	.	.	.	.	.
	BL	.	.	.	.	.	.
			MAXILLARY TEETH				
RI1	MD	.	4.2	5.7	5.2	4.2	4.8
	BL	.	5.5	.	6.4	6.6	6.2
RI2	MD	.	4.4	.	5.9	5.4	5.9
	BL	.	6.3	.	5.8	6.2	6.8
RC	MD	.	5.9	.	.	6.0	6.7
	BL	.	8.1	.	.	8.9	8.7
RP1	MD	.	6.0	.	.	.	7.0
	BL	.	7.2	.	.	.	8.6
RP2	MD	.	5.9	.	.	.	7.0
	BL	.	7.6	.	.	.	9.1

TABLE 8--Continued

TOOTH		BURIAL FEATURE NUMBER					
		5	9	29	36	38	39
RM1	MD	.	.	11.5	.	.	.
	BL	.	.	10.4	.	.	.
RM2	MD	.	.	.	.	11.4	.
	BL	.	.	.	.	11.2	.
RM3	MD	.	8.7	.	10.6	.	9.8
	BL	.	9.0	.	9.9	.	9.6
LI1	MD	.	.	5.7	5.6	4.3	5.0
	BL	.	.	.	6.4	6.6	6.9
LI2	MD	.	.	.	6.4	5.6	6.0
	BL	.	.	.	7.0	6.0	6.0
LC	MD	.	.	.	7.7	6.5	7.0
	BL	.	.	.	7.5	9.0	8.9
LP1	MD	.	.	.	.	6.2	7.3
	BL	.	.	.	.	8.9	8.5
LP2	MD	.	.	.	.	7.0	7.0
	BL	.	.	.	.	9.3	9.3
LM1	MD	.	.	11.4	.	.	.
	BL	.	.	.	.	.	.
LM2	MD	.	.	.	11.6	.	.
	BL	.	.	.	.	.	.
LM3	MD	.	.	.	11.1	.	10.3
	BL	.	.	.	.	.	10.1

MD is the mesial-distal dimension of the tooth; BL is the buccal-lingual dimension of the tooth. Measurements in parentheses are estimates.

Long bones of the lower limbs are all present in very good condition with the following minor exceptions: greater trochanters of femora are damaged and outer bone table of spongy ends of bones are in many cases slightly eroded off. Both patellae are present in excellent condition. All tarsals and metatarsals of both feet are present as well as fourteen phalanges, four phalangeal fragments, and five sesamoid bones.

The upper limbs were both well preserved, with portions of both scapulae having the glenoid fossae, medial borders, and acromion processes present. The coracoid processes and scapular spines on both sides are present but in poor condition and the lateral borders of the scapulae are broken off. The clavicles are both present, with the right one in slightly better condition than the left (in which a small part of the posterior portion of the lateral end is broken). Long bones of the upper limbs are all present in excellent condition with only a few exceptions: lateral portions of the distal joint surface are broken off the humeri, distal joint surfaces of ulnae have small portions broken off, and a small amount of the outer bone table on all upper limb long bones and on the proximal joint surfaces has flaked off. The distal portion of the left radius is in poor condition. The hands are well represented but not complete. All eight carpals and all five metacarpals of both hands are preserved. Twenty-five out of twenty-eight hand phalanges are present.

TABLE 9

CRANIAL AND MANDIBULAR METRICS FOR INDIVIDUALS FROM SITE 7S-F-68

MEASUREMENT	R FEATURE NUMBER			
	5	9	36	39
Glabello-occipital length*	176	176	.	199
Nasion-occipital length	173	175	.	.
Basion-nasion*	98.7	88.0	.	.
Basion-bregma*	128	118	123	134
Maximum cranial breadth*	143	130	133	151
Maximum frontal breadth	114.6	110.7	114.6	129.1
Bistephanic breadth	104.9	109.9	123.4	.
Bizygomatic breadth*	(113.2)	(123.0)	.	.
Minimum cranial breadth	.	117.2	102.6	127.3
Biasterionic breadth	164	131	104.0	117.1
Basion-prosthion*	(89.3)	(86.0)	99.6	.
Nasion-prosthion*	(65.5)	63.7	.	.
Nasal height	(53.0)	44.4	(47.8)	.
Nasal breadth*	25.2	20.5	.	21.4
Orbit height (left)	(35.1)	32.8	.	.
Orbit breadth (left)	(41.7)	37.2	.	.
Palate breadth (external)	49.4	53.0	59.5	.
Palate length (external)	52.2	47.4	58.4	.
Mastoid height (left)	.	24.9	24.1	.
Bimaxillary breadth	.	.	.	.
Biorbital breadth	94.1	93.2	.	.
Interorbital breadth	17.0	21.9	.	.
Nasion-bregma	103.8	102.6	.	.
Bicondylar breadth	(115.2)	.	.	.
Condyle breadth	20.6	17.2	18.3	19.0
Bigonial breadth	95.4	.	85.4	96.0
Ascending ramus height	57.2	54.9	41.5	.
Ascending ramus breadth (min)	24.6	26.6	23.9	30.6
Symphysis height	24.1	28.2	35.3	27.2

Measurements marked with an asterisk (*) are those used in the Giles and Elliot (1962) discriminant functions. Measurements in parentheses are estimates. When a measurement can be taken on either the right or the left side of the skull the left measurement is given, unless it is not present in which case it is replaced by the right measurement. All measurements are given in millimeters. Measurements made with sliding calipers are given to the nearest tenth of a millimeter. Other measurement were made with spreading calipers or a flexible tape.

TABLE 10

POSTCRANIAL METRICS FOR INDIVIDUALS FROM SITE 7S-F-68

MEASUREMENT	FEATURE NUMBER					
	5	9	15	36	39	40
Femur						
Maximum length	455	427	.	454	420	.
Bicondylar length	453	423	.	451	418	.
AP diameter (midshaft)	31.7	25.1	.	24.6	26.1	.
ML diameter (midshaft)	30.5	21.7	.	25.8	27.9	.
Midshaft circumference	101	75	.	78	83	.
AP diameter (subtroch.)	30.5	24.5	.	24.3	28.9	.
ML diameter (subtroch.)	37.5	27.2	.	30.9	33.0	.
Subtroch circumference	109	78	.	89	98	.
Vertical head diameter	(49.7)	40.9	.	41.5	46.1	41.7
Tibia						
Maximum length	397	240	.	356	344	.
AP diameter (midshaft)	29.4	26.9	.	26.7	28.6	.
ML diameter (midshaft)	23.8	18.5	.	19.8	19.7	.
Midshaft circumference	83	69	.	74	75	.
Fibula						
Maximum length	371	.	.	.	.	.
Innominate						
Acetabular height	58.8	46.7	44.9	49.3	51.2	.
Acetabular breadth	58.1	50.9	49.4	(44.7)	51.5	.
Pubic length	96.1	83.2	.	.	.	.
Acetabulosymphyseal	76.7	63.8	.	.	.	.
Trans. diameter inlet	127.2	.	.	.	.	.
Clavicle						
Maximum length	155	.	.	.	.	.
Midshaft circumference	40	.	.	.	.	.
Scapula						
Glenoid cavity height	40.0	.	.	.	.	.
Glenoid cavity breadth	27.2	.	.	.	.	.
Humerus						
Maximum length	326	302	286	.	.	.
Max diameter (midshaft)	26.3	18.1	19.9	.	.	.
Min diameter (midshaft)	24.4	15.6	16.1	.	.	.
Midshaft (circumference)	76	53	61	.	.	.
Vertical head diameter	50.9	41.8	.	.	.	.
Ulna						
Maximum length	275	.	218	.	.	.
Max diameter (midshaft)	16.5	.	14.6	.	.	.
Min diameter (midshaft)	12.5	.	11.8	.	.	.
Min circum (midshaft)	47	.	41	.	.	.

TABLE 10--Continued

MEASUREMENT	FEATURE NUMBER					
	5	9	15	36	39	40
Radius						
Maximum length	249	.	211	.	227	.
AP diameter (midshaft)	10.9	.	14.6	.	13.9	.
ML diameter (midshaft)	14.3	.	11.0	.	12.2	.
Circum (midshaft)	43	.	39	.	41	.

All measurements are given in millimeters. Measurements made with sliding calipers are given to the nearest tenth of a millimeter. Other measurements were made using spreading calipers, a flexible tape, or a bone board. AP is Anterior-posterior. ML is Medial-lateral.

b) *General Description and Pathology*

1) Cranium

Internally the sutures are obliterated, externally they are well knit together (and along the sagittal suture obliterated in the middle portion of the suture). Virtually all teeth were lost **antemortem**. Both the mandibular and maxillary alveoli show considerable **resorption**, with only a few tooth sockets remaining. On the mandible (see Plates 20 and 21), there has been complete resorption of the **alveolus** following tooth loss, in the premolar and molar region. There is some reactive pitting on the right side, suggesting that the right molars had been lost most recently. Anteriorly, two sockets are present on the right side (probably for RI_2 and RC). On the maxilla (see Plate 22), less resorption had taken place at the time of death. Four teeth are present: LC, LM^1, LM^3 and an unidentifiable crown of an anterior tooth. The canine crown is worn and has a considerable amount of **dentin** exposure. The first molar was apparently somewhat rotated in the alveolus. It shows some wear (rounding of the cusps) but no dentin exposure (wear stage 3, following Smith, 1984). The third molar is worn more than the first, with two very small patches of dentin exposed (wear stage 4, following Smith, 1984). This pattern is unusual since the first molars erupt earlier than the third molars and people usually chew on the more anterior molars. Such a pattern of wear reflects the pathological condition of this individual's dentition (he was probably chewing further back in his mouth than one normally would to avoid pain or tenderness as a result of pathological areas of his dentition closer to the front of his mouth). In addition, the third molar has a carious lesion in the center of the **occlusal** surface of the crown, another just above the **cemento-enamel junction**, and one on the root. Three tooth roots (with the crowns decayed and/or worn in two cases) are present. These are lower anterior teeth. Two are RI_2 and RC. The crown of RI_2, for example, has decayed completely, leaving only the root. Given the extreme resorption of the mandibular and maxillary alveoli, it is quite possible that the teeth present here were the only ones remaining at the time of the individual's death.

There is little non-dental pathology on the cranium. There is very slight porosity of the bone on the occipital bone just below lambda and around the foramen magnum, on the frontal just anterior to bregma and just inferior to the glabellar region, and slightly more developed pitting and reactive bone on the right zygomatic close to the zygomaxillary suture (see Plate 23). This pitting is probably **porotic hyperostosis**, which is of unknown etiology but is probably associated with nutritional anemias of various ultimate causes. Both cranial and mandibular surfaces of the temporo mandibular joint are free of osteoarthritis. The occipital condyles have slight development of marginal **osteophytes** resulting in lipping.

TABLE 11

STATURE RECONSTRUCTION FROM LONG BONE DIMENSIONS
FOR INDIVIDUALS FROM SITE 7S-F-68

LONG BONE(S)	LENGTH (cm)	RECONSTRUCTED STATURE (cm)	RECONSTRUCTED STATURE (inches)
Feature 5 (using formulae for White Males)			
Femur	45.6	169.9 +/- 3.27	66.9
Tibia	39.7	178.6 +/- 3.37	70.3
Femur+Tibia	85.3	174.2 +/- 2.99	68.6
Ulna	27.5	175.8 +/- 4.32	69.2
Radius	25.1	173.9 +/- 4.32	68.5
Humerus	32.6	170.8 +/- 4.05	67.3
Feature 9 (using formulae for White Females)			
Femur	42.6	159.3 +/- 3.72	62.7
Tibia	34.0	160.1 +/- 3.66	63.0
Femur+Tibia	76.6	159.7 +/- 3.55	62.9
Humerus	30.2	159.4 +/- 4.45	62.7
Feature 15 (using formulae for White Females)			
Ulna	21.8	150.8 +/- 4.30	59.4
Radius	21.1	154.9 +/- 4.24	61.0
Humerus	28.6	154.0 +/- 4.45	60.6
Feature 36 (using formulae for White Females)			
Femur	45.4	166.2 +/- 3.72	65.4
Tibia	35.6	164.7 +/- 3.66	64.9
Femur+Tibia	81.0	165.8 +/- 3.55	65.3
Feature 38 (using formula for White Males)			
Ulna	24.8	163.6 +/- 4.30	64.4
Feature 39 (using formulae for White Males)			
Femur	42.3	162.1 +/- 3.27	63.8
Tibia	34.4	165.3 +/- 3.37	65.1
Femur+Tibia	76.7	163.0 +/- 2.99	64.2
Radius	22.7	164.8 +/- 4.32	64.9
Humerus	29.7	161.9 +/- 4.05	63.7

For each individual, stature is reconstructed using sex-appropriate regression formulae from Trotter (1970) for Whites. Statures estimated from all available long bones are provided.

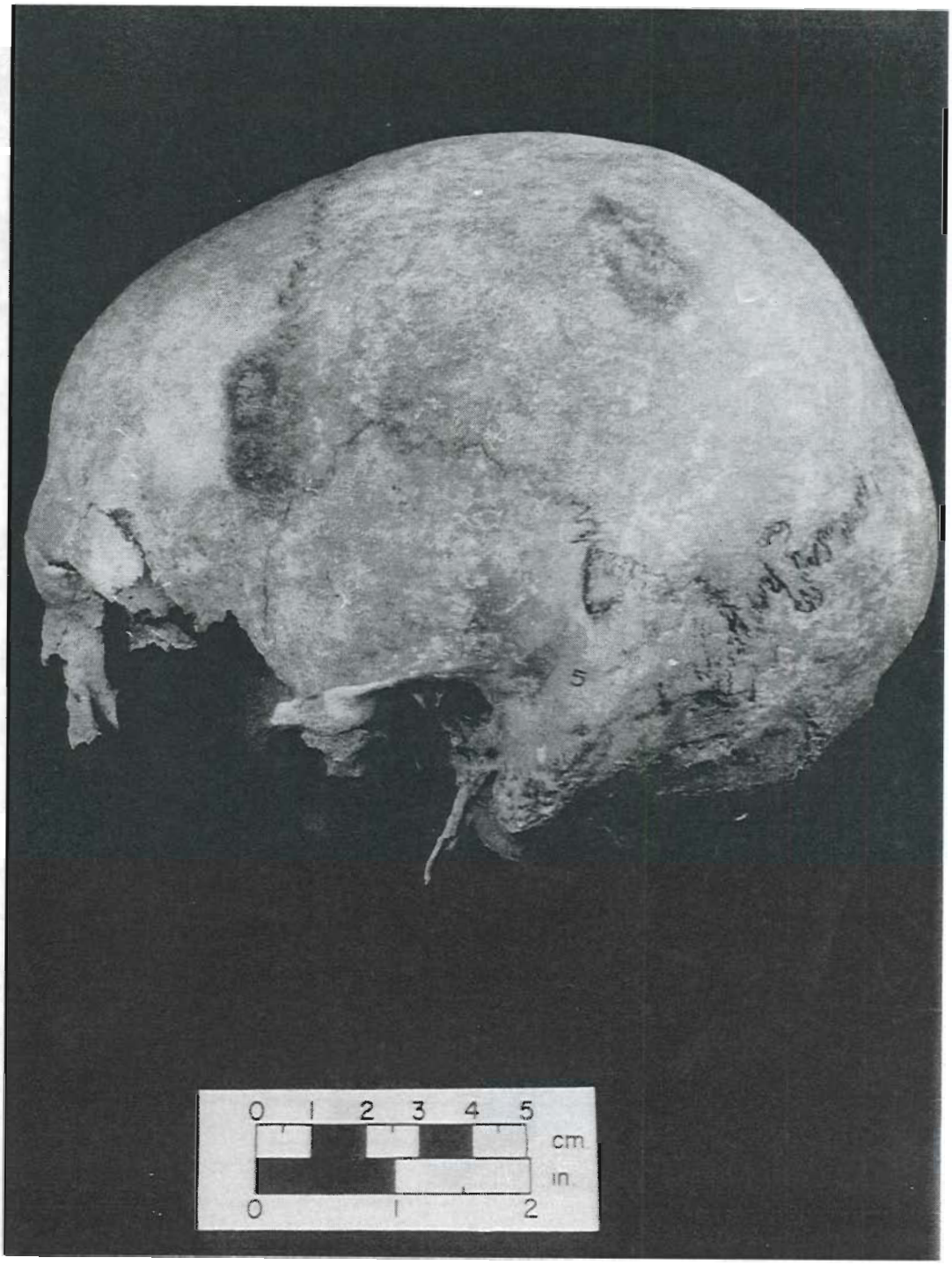

PLATE 18: Cranium of the Individual from Feature 5 in Lateral View (Left Side).
Note the moderately large mastoid processes and roughened area in the nuchal region (at the back of the skull) and the green staining on the frontal at the coronal suture just below the temporal line and on the left parietal.

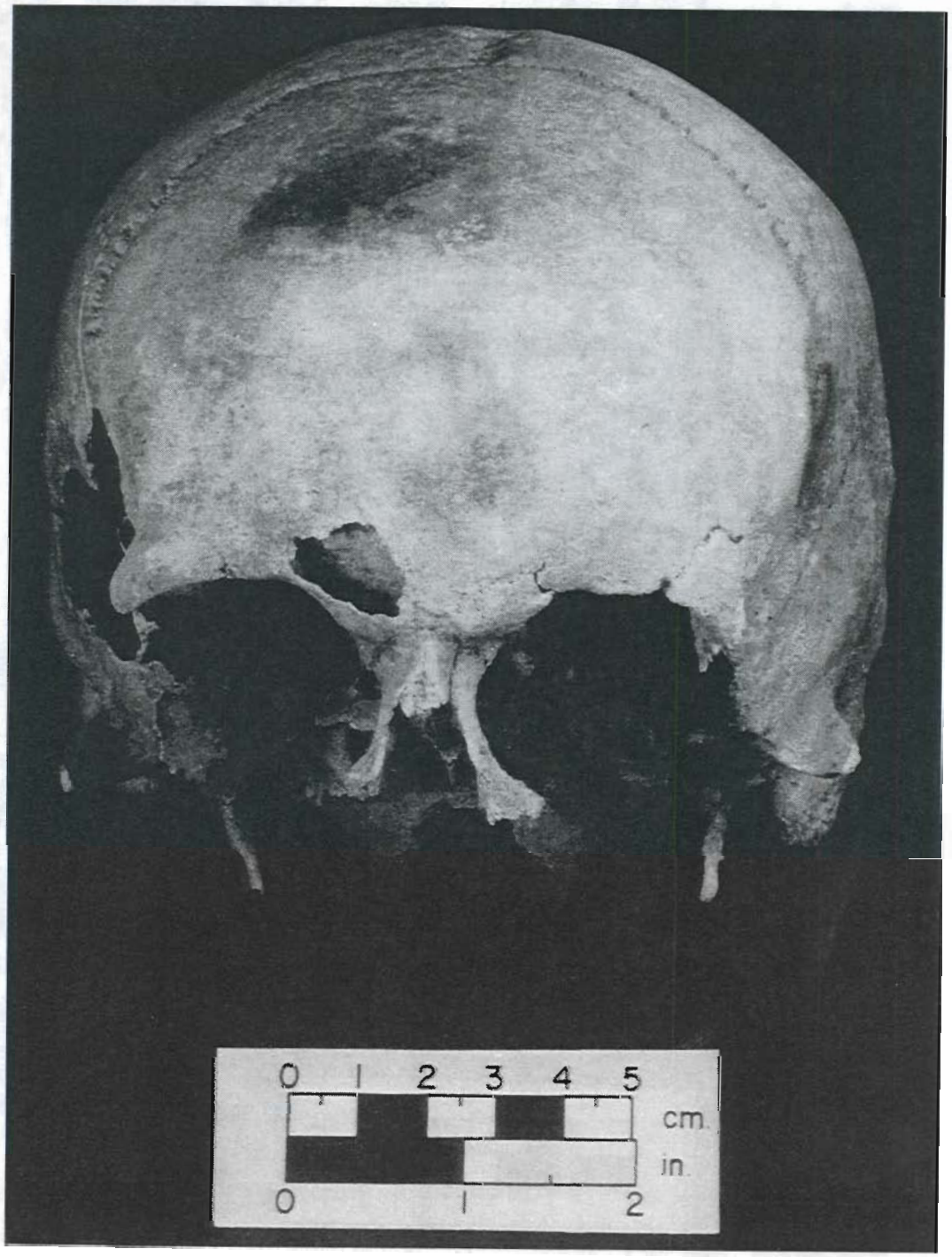

PLATE 19: Cranium of the Individual from Feature 5 in Frontal View.
Note the staining on the frontal just to the right of the midline and on the left frontal and parietal.

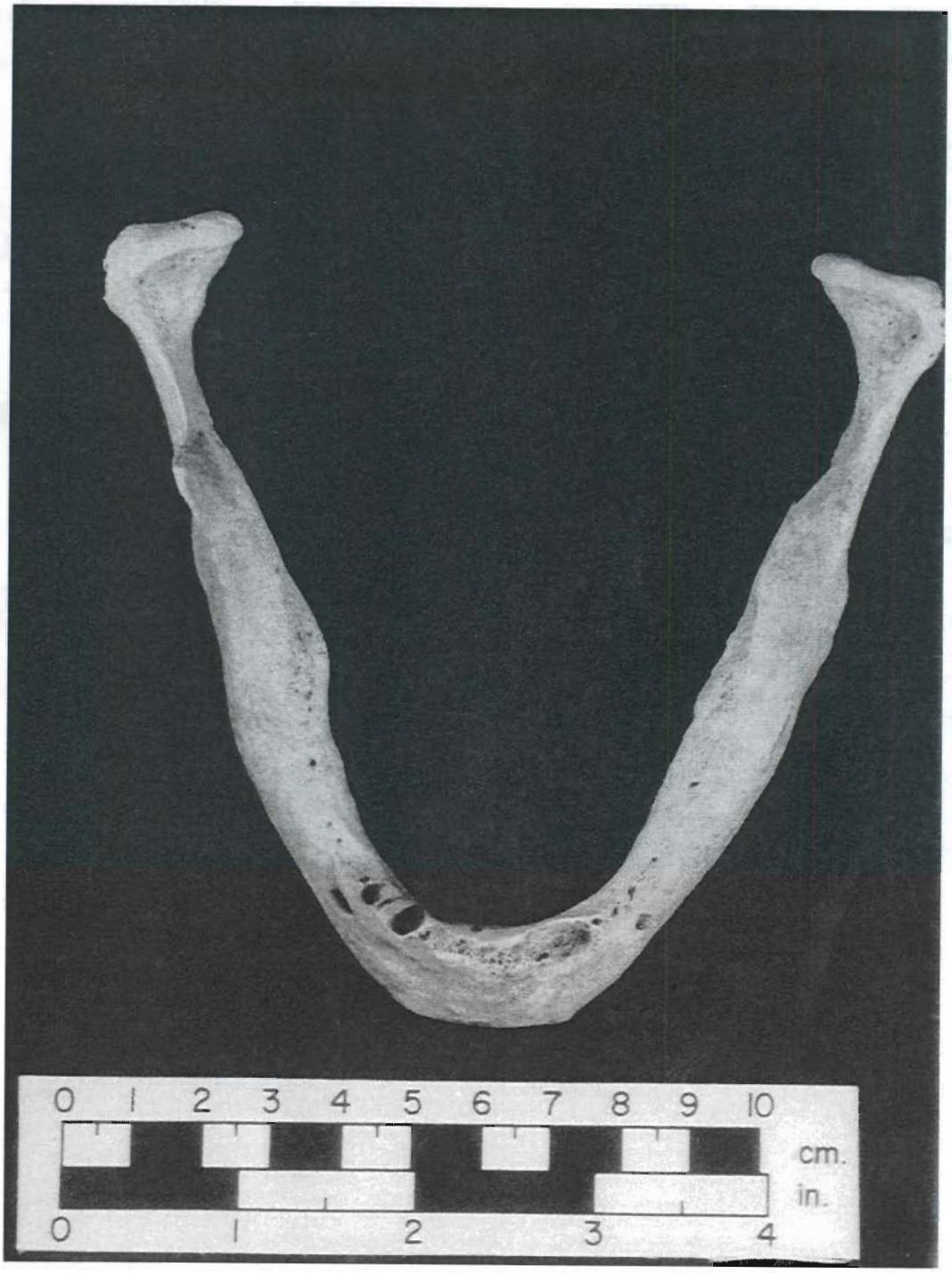

PLATE 20: Mandible of the Individual from Feature 5 in Occlusal (Superior) View.
All teeth in the molar and premolar region were lost antemortem and there has been a considerable amount of alveolar resorption (more on the left than on the right side) following tooth loss. Anteriorly, at least some teeth were present at the time of death.

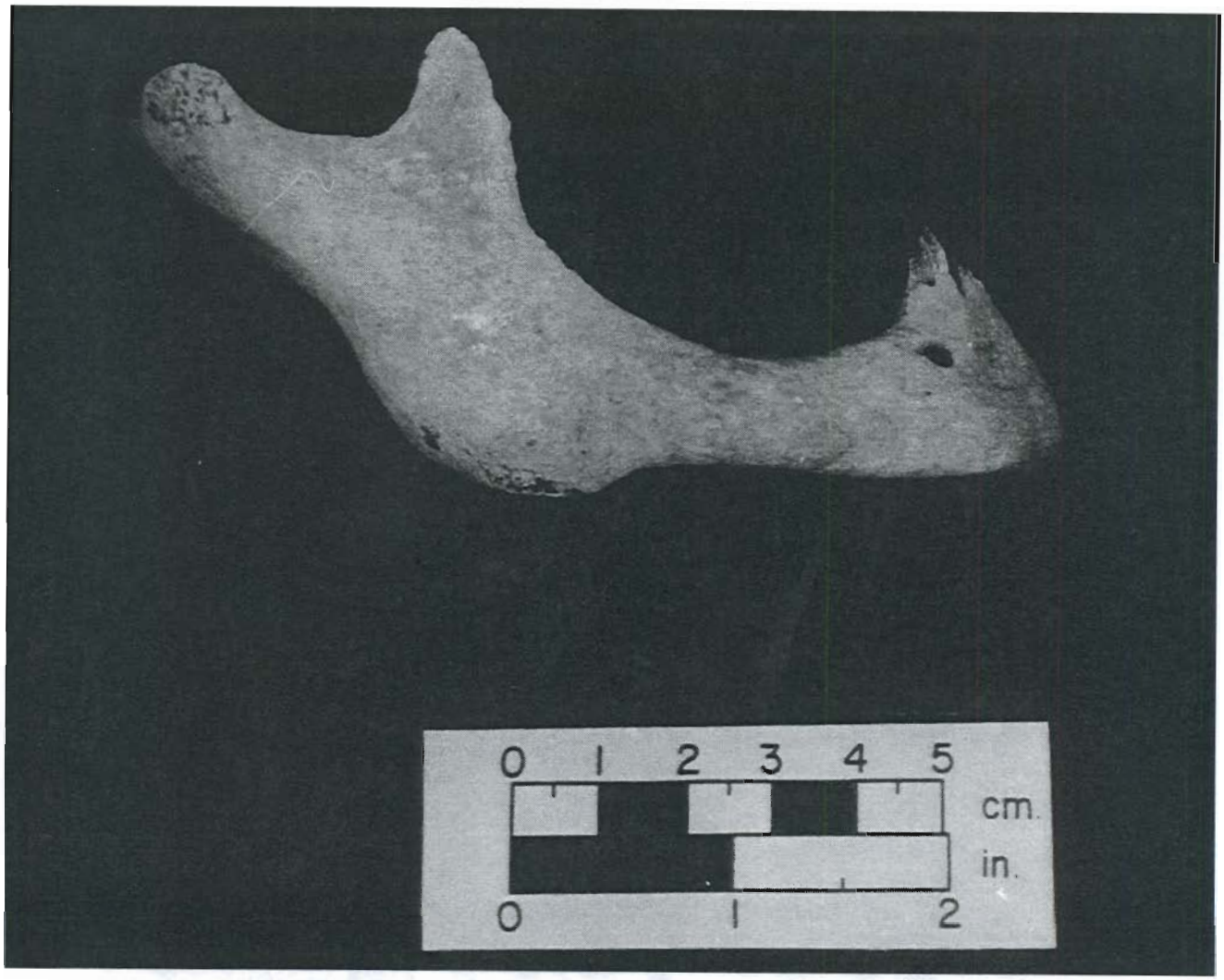

PLATE 21: Mandible of the Individual from Feature 5 in Lateral View (Right Side).
Note the extreme degree of alveolar resorption that has taken place following the loss of the cheek teeth so that the mandible in the cheek teeth region is extremely thinned.

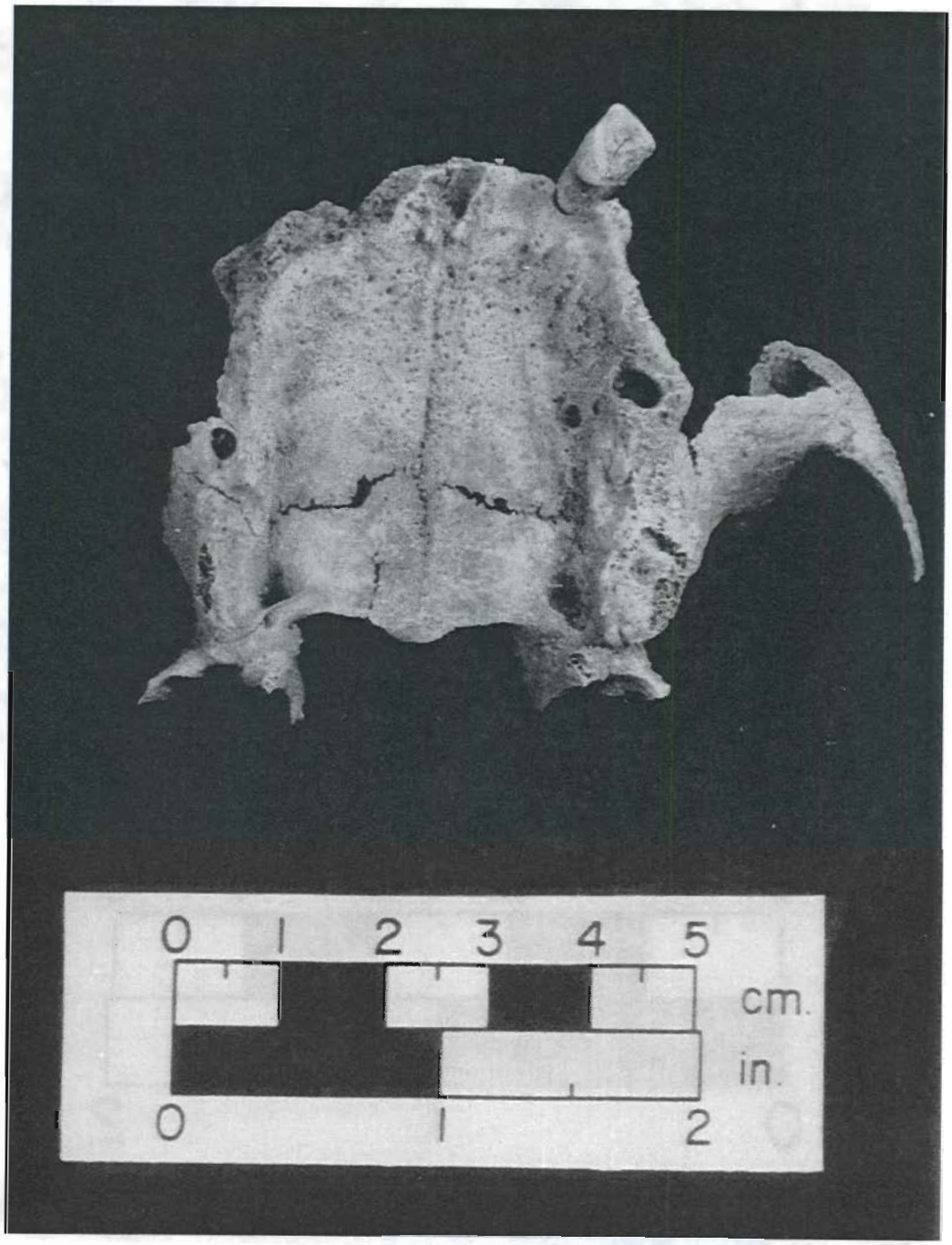

PLATE 22: Maxilla of the Individual from Feature 5 in Occlusal (Inferior) View.
More teeth remained on the maxilla than on the mandible at the time of death, but there was still a good deal of alveolar resorption following tooth loss.

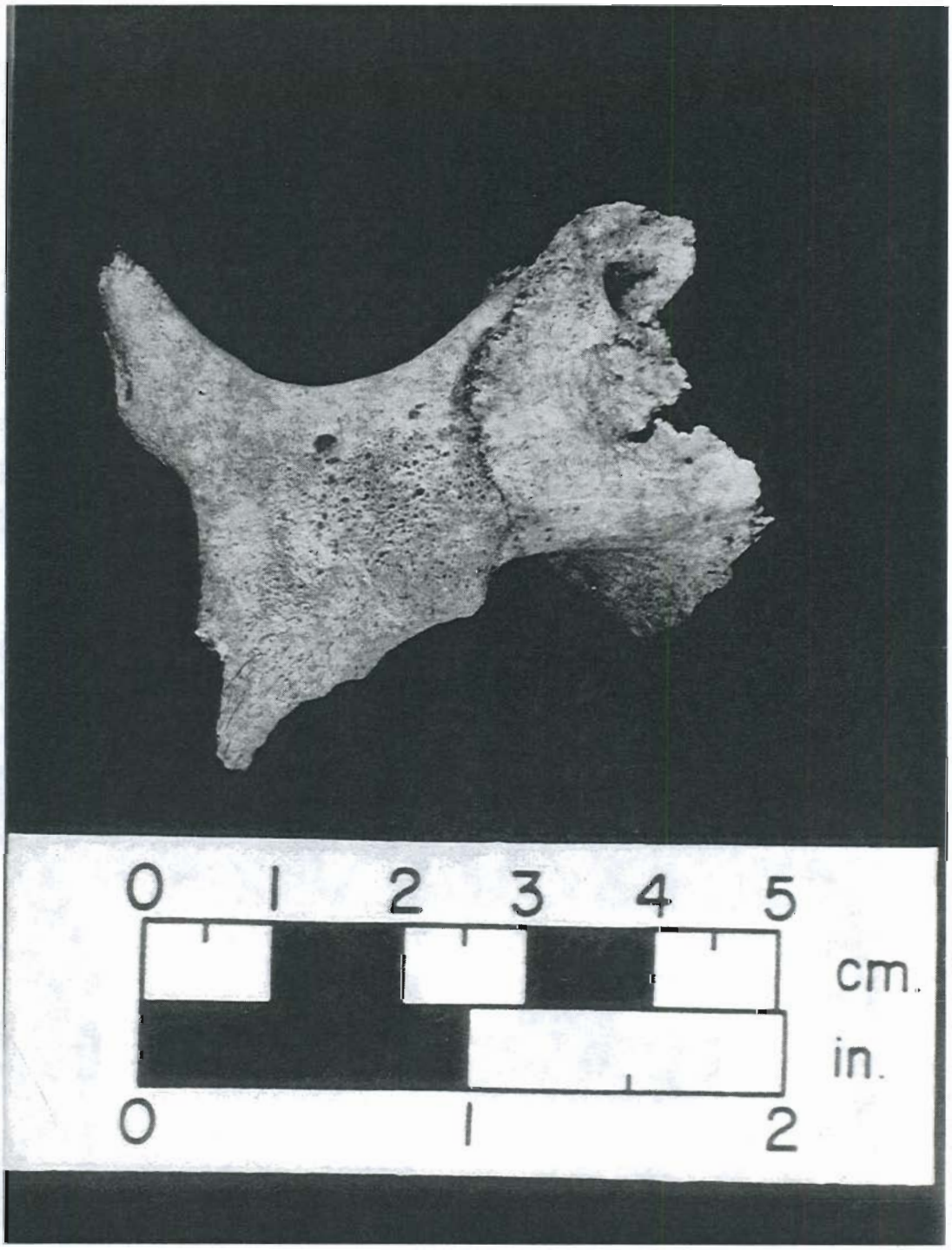

PLATE 23: The Right Zygomatic Bone and a Portion of the Maxilla of the Individual from Feature 5.
The right side of the picture is towards the midline of the body.
Note the pitting and reactive nature of the bone (Porotic Hyperostosis).

2) Vertebral Column

There is one large marginal osteophyte on the articular facet for the dens on the atlas (C1) and moderate marginal osteophytic development on the dens (C2) and on the bodies of all the other cervical vertebrae, so that they are quite lipped, with the involvement increasing as one moves from the upper to the lower portion of the cervical portion of the vertebral column. "Macroporosity and distortion" (Mann and Murphy, 1990) of the articular facets is present on C6 and C7, with the maximum being on C7. The right sides of C6 and C7 are more severely affected than the left. There are small osteophytes posterior to the superior articular facets on the fifth and sixth cervical vertebrae.

The first thoracic vertebra has marginal osteophytes on the body resulting in "beak shaped" lipping. The surface of the vertebral body is slightly porous. There are very small longitudinally oriented bony spurs (laminar spurs) on the superior posterior surface of the vertebral canal. The second thoracic vertebra is similar to the first, with additional larger laminar spurs along the posterior portion of the vertebral canal. Small bony spurs occur along the margin of the vertebral foramen. There are marginal osteophytes on the anterior surface of the vertebral body on T1, T2, T5, T6, and T11. The third, fourth, and fifth thoracic vertebrae are fused to each other and on the right side to two ribs (see Plate 24). The sixth thoracic vertebra is fused to a right rib. The eighth through eleventh thoracic vertebrae are fused to each other (see Plate 25). In all cases the fusion is greater on the right side than on the left, with the line of articulation on the right side between adjacent vertebrae being obliterated, while on the left side the line of articulation between the adjacent vertebrae is still visible though fusion has taken place. The third and fourth thoracic vertebrae are fused to one another completely on all sides. Throughout the thoracic vertebrae the fusion occurs not only on the articular surfaces of the vertebral bodies but extends to the superior and inferior articular facets and in some cases even to the spinous processes (inferiorly on the column). This fusion of thoracic vertebrae causes the vertebral column to be curved laterally toward the right side, with some of the vertebral bodies being "twisted" as described by Mann and Murphy (1990) as typical of **scoliosis** resulting from **osteoporosis** and collapse of the vertebral bodies (see Mann and Murphy 1990:Figure 21, p. 57). They describe the fusion of vertebral bodies as "**spondylosis deformans**," which is "the most common degenerative spine disease affecting males much more frequently than females" (Mann and Murphy 1990:57).

The first four lumbar vertebrae are not fused to each other. The fifth lumbar vertebra is fused to the sacrum and innominate (see below). In L1-L4 there seems to be only slight lipping of the vertebral bodies; however, as the outer surface of the vertebral bodies is not present, the extent of lipping cannot really be determined. Osteophytic development appears on the superior posterior surface of the body of L3 with a small corresponding development on the body of L2. There are marginal osteophytes on the superior articular facets of L1, L2, and L4. On L3, because the articular facet is in poor condition it is not possible to see whether or not there were osteophytes. On L2 there is an area of macroporosity on the superior surface of the vertebral body. On the other lumbar vertebrae, the surfaces of the body are somewhat porous.

All of the bony pathology of the vertebral column is the result of age-related osteoporosis, degeneration, and osteoarthritis.

3) Pelvis

The fifth lumbar vertebra is fused to the sacrum and ilia. This fusion extends not only to the sacroiliac joint but to an articulation between the lateral portions of L5 and the posterior superior portions of the iliac blades. The body of L5 exhibits lipping similar to that seen in the upper lumbar vertebrae with small marginal osteophytes of the superior articular facets. The sacroiliac articulation is completely fused and the lines of articulation between these bones is completely obliterated (see Plate 26). There are marginal osteophytes on the borders of the acetabula, with this

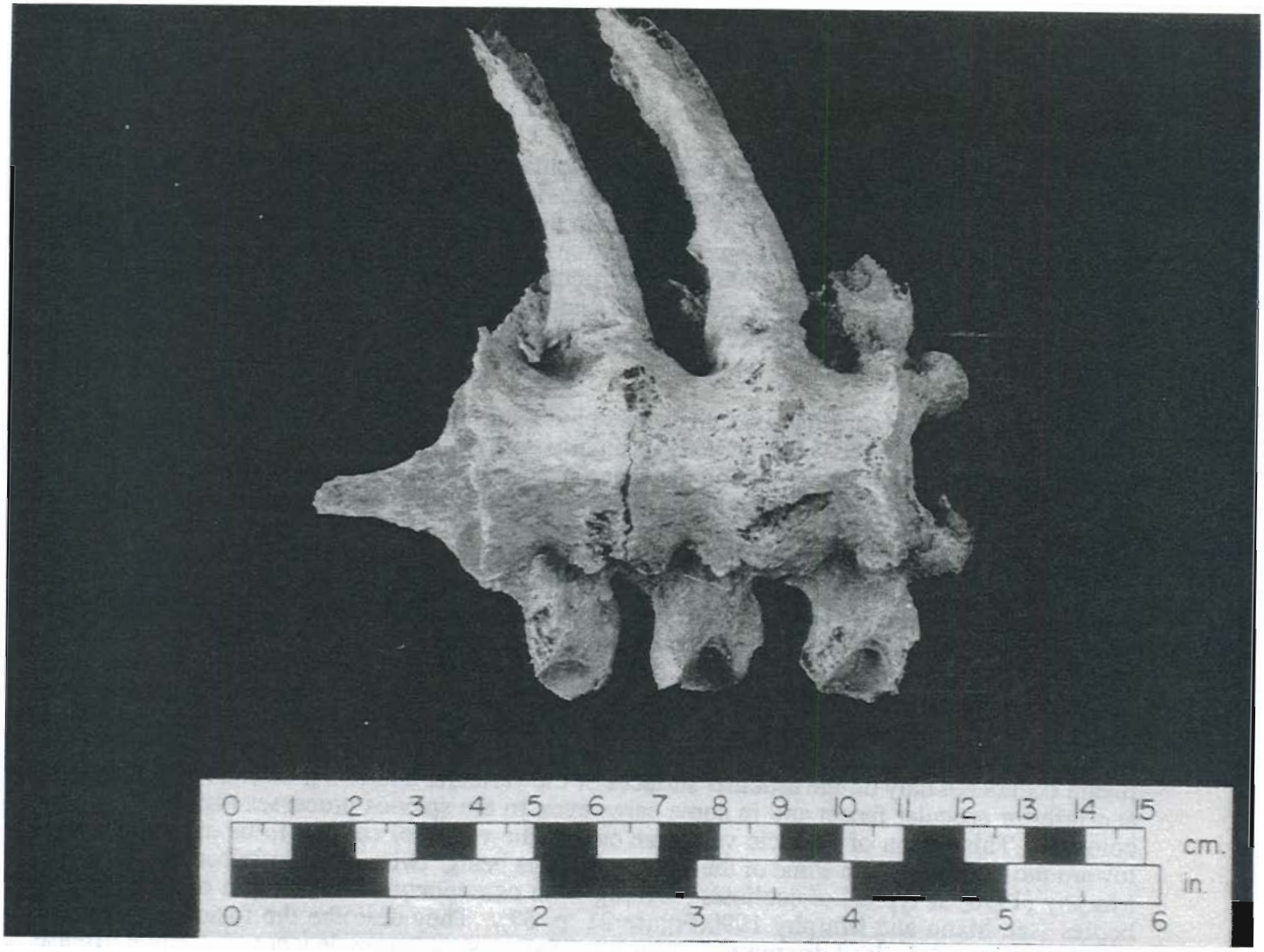

PLATE 24: Upper Thoracic Vertebrae (T3, T4 and T5) and Attached Ribs from the Individual from Feature 5 in Anterior View.

Superior is to the Right in this Picture. These vertebrae are fused to one another and to the right ribs as a result of "Spondylosis Deformans", a commonly occurring degenerative spine disease associated with aging.

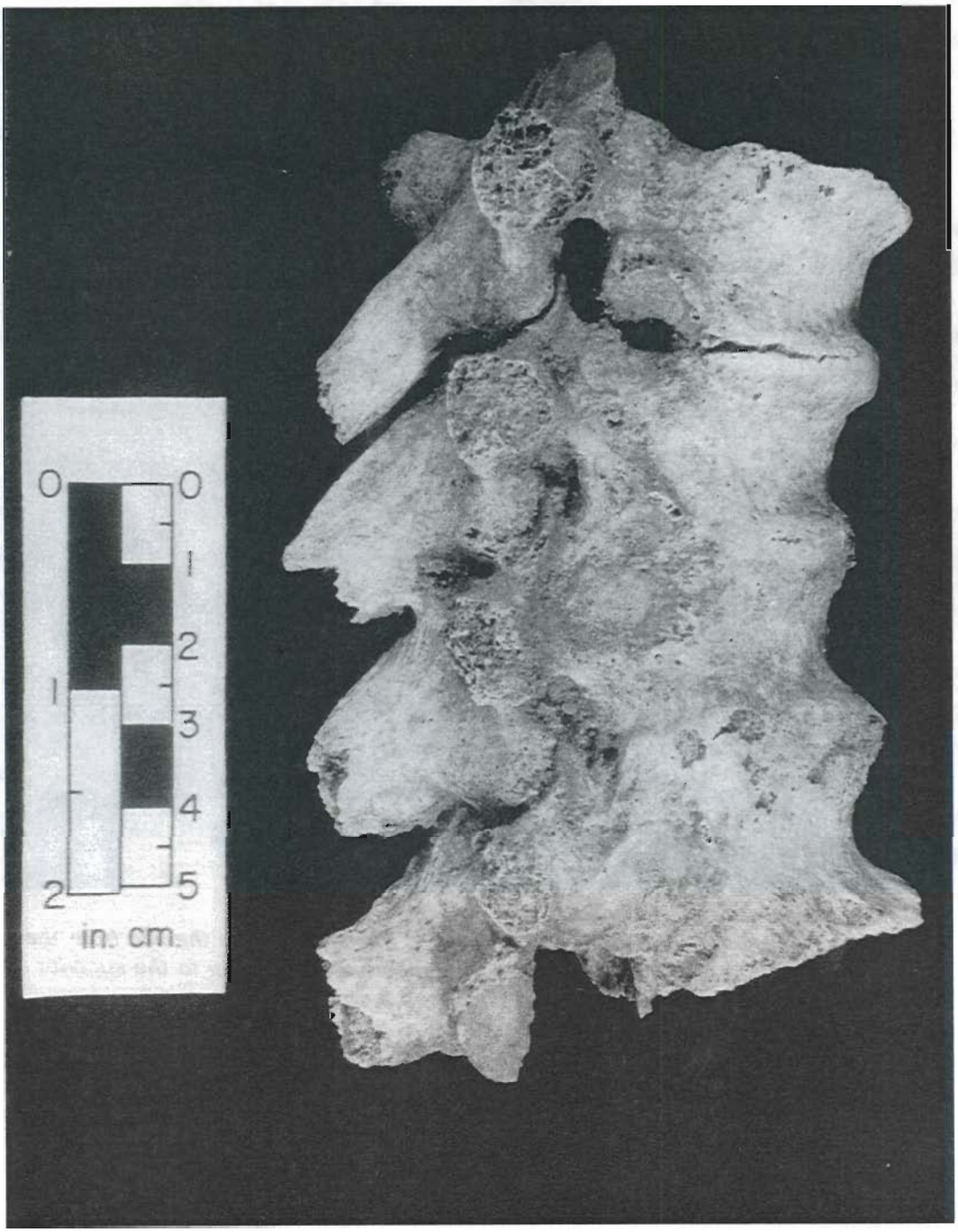

PLATE 25: Lower Thoracic Vertebrae (T8-T11) from the Individual from Feature 5 in Lateral view.
Inferior is to the bottom in this picture, and anterior is to the right. Note that these vertebrae are fused together at the vertebral body articulations as well as at the spinous processes.

PLATE 26: The Pelvis from the Individual from Feature 5.

Note that the innominate are both fused to the sacrum with the line from the sacroiliac articulation being virtually obliterated and the fifth lumbar vertebra fused to the superior articular surface of the sacrum as well as to the iliac blades on both sides.

condition being more severe on the right. A roughened area (not pathological) is present above the lateral portion of the acetabulum. There are no preauricular sulci, but fusion of the ilium to the sacrum could have obliterated them had they been present earlier in life. Spike-like projections (**enthesophytes**) occurring on the iliac crest seem to represent ossification of tendon attachments. These are more pronounced on the left side.

The acetabula are extremely large. The ischial tuberosities are large and robust. Although the sciatic notch is fairly wide, the two sides are asymmetrical, making it look more male-like than female-like in shape. The pubic bone is fairly short relative to the acetabulum. The surface of the pubic symphysis is largely destroyed, but appears to have been quite smooth and lacking the rugosity typical of young individuals.

4) Ribs, Manubrium, and Sternum

The manubrium was fused completely on both sides to the first ribs with the line of fusion obliterated. As mentioned above, several ribs (right third through sixth) are fused to their vertebrae. Where articular surfaces of ribs are visible and preserved there is slight lipping on these surfaces.

5) Lower Limb

Each femur has an extremely well developed linea aspera with ossification of ligament and tendon attachments (enthesophytes). The margins of the articular surfaces of both the femoral heads and the distal surfaces are not preserved so that it is impossible to assess the degree of lipping of these surfaces. There is a small degree of osteophytic development on the fovea capitis on both sides.

On both patellae the marginal portions of the joint surfaces are badly preserved, so that as on the femur, it is impossible to assess the degree of lipping of these articular surfaces. The central portions of the joint surfaces are smooth, with no porosity.

The tibiae have extremely well developed enthesophytes of the attachment sites of the popliteal line in the area near the nutrient foramen. Joint surfaces are all smooth, with no porosity. The bone on the anterior surface of both tibiae has linear striations. The regions on the lateral surface of the bones around the area of the distal and proximal articulation with the fibulae seem to have some osteophytic development.

The superior articular surfaces of both fibulae have slight osteophytic development and lipping.

The tarsals have slight ossification of the Achilles tendon attachments (enthesophytes) and slight lipping of the joint surfaces.

Where it is possible to see the margins of the joint surfaces of the metatarsals and phalanges, there is extremely slight lipping.

6) Upper Limb

The clavicles have lipping and moderate porosity on the articular surfaces of the sternal heads. Areas of muscle attachment have slight osteophytic development.

The glenoid fossae of the scapula have smooth surfaces, with moderate marginal osteophytic development resulting in mild lipping. On the right side, there is some osteophytic development on the tip of the acromion process and on the coracoid process as well. The latter may be a manifestation of an uncommon phenomenon identified by Mann and Murphy (1990) as a conoid joint for articulation with the inferior surface of the clavicle. A corresponding surface seems to

exist on the right clavicle. The acromion process on the left scapula is not preserved, but a similar "raised plateau-like bony extension" appears on the left clavicle (Mann and Murphy 1990:82).

The humeri are asymmetrical in the development of the deltoid tuberosity -- it is somewhat larger on the right humerus. This is true not only just below the head of the bone, but also in the lower half of the humeral shaft. Joint surfaces appear to be smooth, but in many cases their margins are not preserved. Olecranon fossae are not perforated.

The joint surfaces of the radii are smooth. Although many articular surface margins are not well preserved, the right radius has moderate marginal lipping on its distal articular surface. The radial tuberosities on both sides have bony development (enthesophytes) (more on the right side than on the left). The region just inferior to the ulnar notch on the ulna has similar development. On both ulnae, the trochlear notch has a slight transverse ridge of bone extending across the articular surface.

Where it is possible to examine them, the carpal bones have mild marginal osteophytic development resulting in lipping on some of their articular surfaces.

c) *Sex*

This individual is almost certainly male. As discussed above, the pelvis has a large acetabulum, an asymmetrical sciatic notch, and a short superior pubic ramus, all indicative of a male. In addition, the long bones of the postcranial skeleton are large and robust. The cranium is neither large nor extremely robust, but has a roughened area at inion, supraorbital tori which are moderately developed at glabella with some development laterally, but very little over the middle portion of the orbit. Application of the Giles and Elliot (1962) discriminant function for sex determination based on cranial measurements produces a value for the discriminant function which classifies the individual as female. However, there are several reasons for following the diagnosis of male based on the pelvis, rather than the diagnosis of female based on cranial metrics. First, pelvic morphology is in general a better indicator of sex than cranial morphology or than discriminant functions based on cranial metrics (Meindl et al. 1985), and the pelvic morphology is very convincingly male. Second, because of the condition of the skull, two of the cranial measurements (basion-prosthion and prosthion-nasion) used in the discriminant function were estimated and further reduce confidence in the accuracy of the discriminant function. Finally, although the discriminant function is based on a sample of White Americans, it is a different population from the one from which this specimen is derived and must therefore be used with caution. In short, the indicators pointing to male for this specimen are much more convincing than those pointing to female, and the specimen is almost certainly male.

d) *Age*

The great amount of antemortem tooth loss, osteoporosis, osteoarthritis, and fusion of the endocranial sutures all indicate that this individual was well into adulthood. The small portion of pubic symphysis which is preserved is consistent with such a statement. The individual was probably 50-60+ years old at the time of death.

e) *Cultural Modifications*

The skull has several green stains (presumably from contact with copper in the form of shroud pins). One (31.0 mm x 13.7 mm) is on the frontal just to the right of the midline about two thirds of the way from the supraciliary arches to the coronal suture (see Plate 19). A second (19.8 mm x 9.3 mm) is on the coronal suture on the left side, just inferior to the temporal line (see Plate 18). A third (26.4 mm x 13.7 mm) is on the left parietal approximately at the point of maximum cranial breadth, just posterior-superior to the temporal line (see Plate 19). There is also a stain (13.9 mm

x 8.4 mm) on the mandible at the symphysis, more on the left side than on the right, but overlapping the midline.

On the right radius at the distal end there is a slight green stain on the anterior surface of the bone (see Plate 27). This stain corresponds to a longitudinal cut mark which has green staining within the bone, and the cut mark has a shiny surface inside. The green stain also occurs on the anterior margin of the articular surface and the cut mark extends to that point. A possibility is that this represents the remains of a shroud pin which was actually inserted into the bone at the wrist. No green staining occurs on any of the adjacent carpals, though there is a very diffuse greenish-yellow stain on the lateral side of the first metacarpal.

f) *Stature*

Based on the formula for stature reconstruction for American White Males (Trotter 1970), using femoral and tibial length, this individual's stature was 174.2 +/- 2.99 cm (68.6 inches). Reconstruction of stature based on the other long bones (fibula, humerus, radius, and ulna) all have overlapping ranges with this estimate (see Table 11). Given the osteoporosis of the vertebral column and the advanced age of the individual, stature close to the time of death was probably somewhat shorter.

g) *Population Affinity*

This specimen is almost certainly from an individual of European ancestry. There seems to be a nasal sill and the zygomatic arches are retreating, both typically Caucasoid features. The interorbital region shows a frontal process which is angled away from the nasal bones as Gill and Gilbert (1990) argue is characteristic of Europeans. The form of the zygomaxillary suture seems to be of the "angled" form rather than the "curved" form. This form is more often characteristic of "Mongoloids" than of "Caucasoid" (Rhine 1990). The chin seems to have a bilateral projection as is often the case in Europeans (Gill 1986). On balance this individual has mostly "Caucasoid" features. Analysis of cranial metrics using discriminant functions (to distinguish between Whites and Blacks and Whites and Indians, in both cases using functions for males) from Giles and Elliot (1962) also classifies this individual as of European ancestry.

h) *Summary*

This was an elderly male individual with evidence of old age in the extensive antemortem tooth loss and extreme osteoarthritis throughout the skeleton and resulting "spondylosis deformans" in the vertebral column. He had no bony pathologies other than these age-related ones. He would have been about 68.6 inches (5 feet, 9 inches) tall during life (prior to the onset of bone loss) and was almost certainly of European ancestry.

2. FEATURE 9

a) *Skeletal Inventory and Condition*

In general the preservation and condition of this skeleton is excellent, with almost the entire skeleton preserved.

The cranium of this individual is complete and in excellent condition (see Plates 28 and 29). There is a crack extending from just posterior to the coronal suture on the right side, down the temporo-sphenoidal suture, through the right occipital condyle, across the foramen magnum, up the left temporo-occipital suture and into the lambdoidal suture. This crack caused the bones to spread apart slightly. The left occipital condyle has broken off. All maxillary teeth which were present at the time of death were preserved (LI^1 through LM^2 and RI^1 through LM^1). The mandible is