g) *Summary*

This skeleton represents the remains of an infant who died at birth or within the first six months of life following birth.

6. FEATURE 36

a) *Skeletal Inventory and Condition*

The skull is complete and in fairly good condition. Recent intrusive activity crushed the superior portion of the face and anterior portion of the cranium (so that the frontal around glabella and the supraorbital region is absent). The face has two horizontal cracks running through it (one through the orbits and one across the upper portion of the maxilla). The mandible is complete, with all the teeth present which were in the jaw at the time of death. On many of the teeth from both the mandible and maxilla, the outer surface of enamel has become separated (delaminated) from the dentin.

Seven cervical vertebrae are present in excellent condition. Only the seventh cervical is somewhat broken. Eleven thoracic vertebrae are present in good condition.

The sternum is preserved in very good condition. The ribs are represented by fragments.

The left innominate is present and in good condition although the posterior portion of the iliac blade, the superior pubic ramus, and the ischiopubic ramus are all broken off. The right innominate is fragmentary.

Both femora are complete. Patellae, tibias, and fibulae are all present and in good condition. The feet are represented by all tarsals, all metatarsals, and most of the phalanges (nine from the proximal row, seven from the medial row, and seven from the distal row). In addition there is one sesamoid bone from the foot.

The scapulae and clavicles from both sides are present. The clavicles are complete, in good condition; the scapulae have the medial borders and other projecting areas missing. Both humeri, radii, and ulnae are present but all in only fair condition. The bones of the hands are represented by six left carpals (the navicular, lunate, triquetral, lesser multangular, capitate, and hamate), three left and two right metacarpals, and seven left phalanges.

b) *General Description and Pathology*

1) Cranium

This skull is fairly gracile, though more robust than the one from Feature 9 (see Plate 36). The brow ridges are absent, but the mastoid processes are small, the temporal lines very faint, and the nuchal region is quite smooth. There is some parietal bossing. Endocranially, the sutures are closed and almost obliterated; on the outer surface they are partially closed and still quite visible. The spheno-occipital synchondrosis is closed and obliterated. All teeth had erupted and were worn or lost antemortem. The individual is clearly adult, but not as advanced in age as Feature 5. No arthritis is visible on either the glenoid fossa of the temporomandibular joint or the occipital condyles. No other bony pathology is evident on the cranium.

The mandible also shows no arthritis on the temporomandibular joint (only the left side can be evaluated) (see Plate 37). Because of the postmortem damage to the teeth, it is somewhat difficult to evaluate pathology or dental wear. All of the teeth (except RP_2 which is absent and may have been lost postmortem) were present at the time of death. The roots of the right M_1 and M_2 are

PLATE 36: The Cranium from the Individual from Feature 36 in Lateral View (Left Side).
The top portion of the face (including the brow ridge region of the frontal bone) was broken off recently (all the bone breaks are fresh). Note the gracility of the skull, especially in the nuchal region and the small mastoid processes, suggesting that this individual was female.

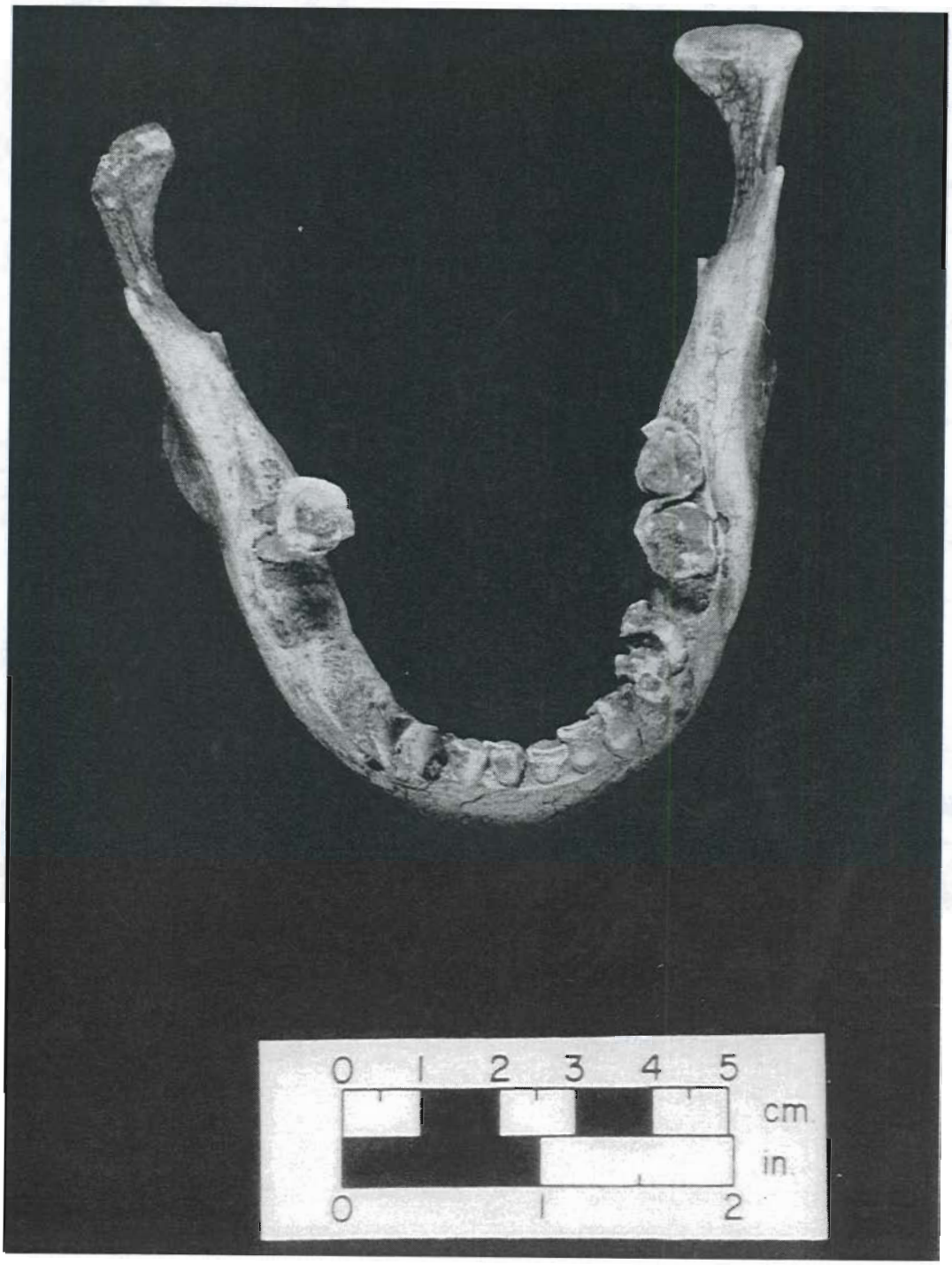

PLATE 37: The Mandible from the Individual from Feature 36 in Occlusal (Superior) View.

Although the teeth show considerable post-mortem damage, so that it is difficult to determine exactly how much dental pathology occurred, it is clear that a considerable amount of dental decay and antemortem tooth loss had taken place in this individual.

present but were clearly extremely decayed at the time of death (M_1 has only the lingual portion of the crown present and the M_2 crown is completely decayed). The region of the alveolus around these teeth has been considerably resorbed, with thinning of the mandibular body, and shows evidence of abscesses associated with both of these teeth. The left M_1 also has a decayed crown, with only the root remaining in the alveolus. The pathology of the other teeth cannot be evaluated because of postmortem damage.

All of the maxillary teeth were present at the time of death (see Plate 38). The central incisors have marginal lingual ridges. The incisors seem to have **interproximal** caries, but because the enamel is broken off the surface of the tooth, it is unclear whether there was dental decay and then postmortem damage to the teeth (possibly greater than it might have been because of the condition of the teeth) or whether there was no dental pathology at the time of death, but postmortem damage which mimics dental decay. The left P^1, P^2, and M^1 seem to have had decayed crowns, but like the other teeth are damaged and difficult to evaluate. The alveolus in the region of left M^1 was in the process of resorption at the time of death.

2) Vertebral Column

The vertebrae are small. The cervical and thoracic vertebrae are essentially free of pathology, with only very slight lipping on the vertebral bodies.

3) Sternum, Manubrium, and Ribs

No pathology is visible on the fragmentary sternum or ribs.

4) Sacrum and Pelvis

Innominates are small and gracile. Acetabula are small, with very slight lipping on the rims. The sciatic notches are very wide and the two sides of the sciatic angle are of similar lengths. Although the pubis is not present, it is clear from the portions of innominate which are preserved that this individual was female. A slight preauricular sulcus is present on both the right and the left side. Although this feature has often been interpreted as evidence that an individual gave birth, the correspondence between such so-called **parturition scars** and parity status remains controversial.

5) Lower Limb

The femora are short and quite gracile. The linea aspera and lesser trochanter are particularly weakly developed. The femora are free of any visible pathology. Tibiae and fibulae are similarly gracile and also free of pathology.

The tarsals and metatarsals have only extremely mild lipping on joint surfaces. No other pathology is visible.

6) Upper Limb

Scapulae and clavicles are gracile and small with no pathology on any of the preserved surfaces. The humeri, ulnae, and radii are all in poor condition, but are small and gracile, with only slightly developed deltoid tuberosities or other muscle markings.

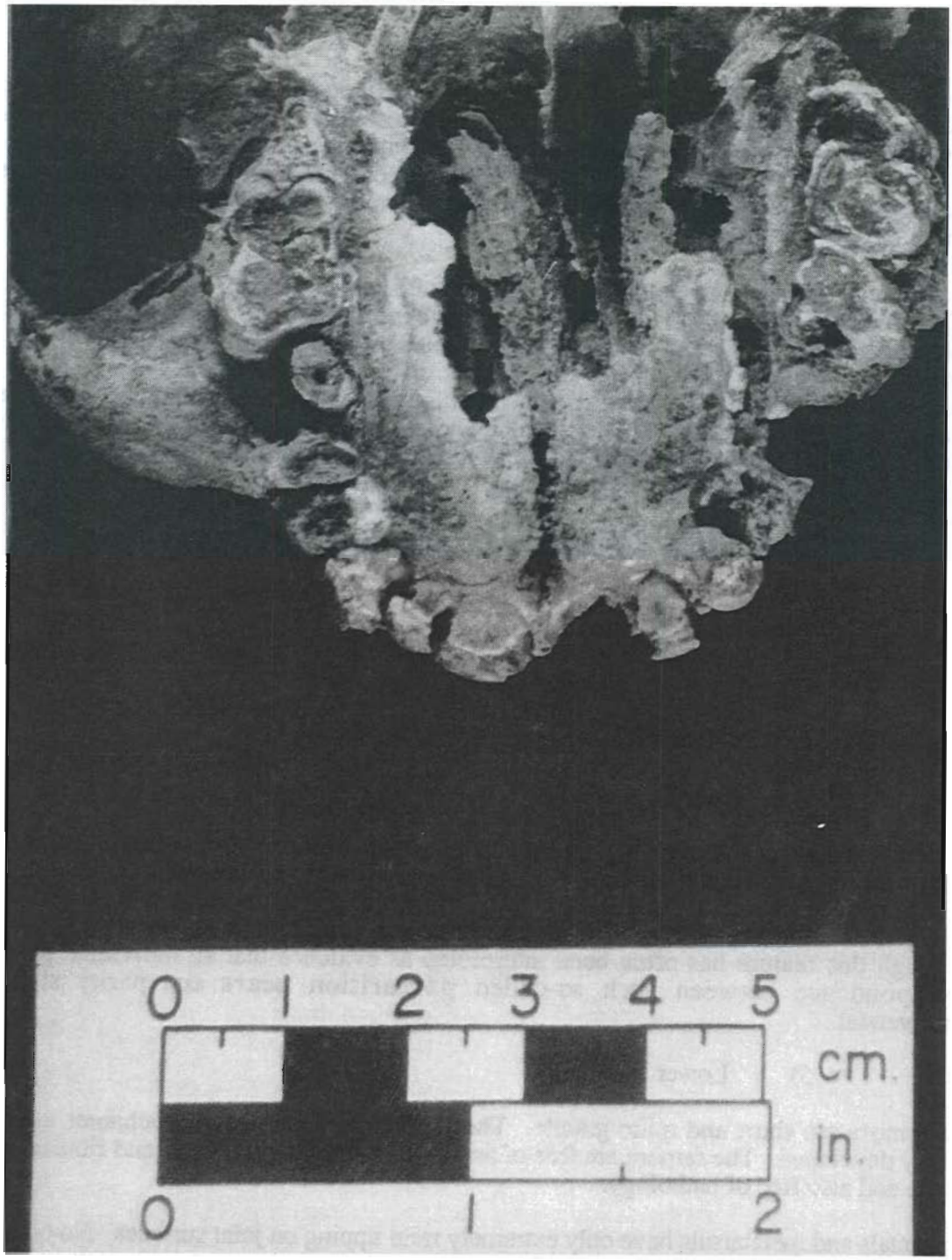

PLATE 38: The Maxilla from the Individual from Feature 36 in Occlusal (Inferior) View.

The teeth were in very poor condition due to post-mortem damage, but some dental decay is clearly visible on the left side in the premolar region and possibly elsewhere.

c) *Sex*

Based on the morphology of the pelvis and the size and gracility of the skull and postcrania, it is clear that this individual was a female. Because the region around glabella is missing, it is not possible to use the Giles and Elliot (1962) discriminant function to classify this specimen either as to sex, or to population affinity.

d) *Age*

This individual is clearly fully adult, given the state of dental eruption and epiphyseal and cranial suture closure. The fact that few teeth were lost antemortem and the lack of osteoarthritis suggest that the individual was not extremely advanced in age (probably in the 30s or 40s at the time of death).

e) *Cultural Modifications*

No evidence of cultural modifications was visible on this skeleton.

f) *Stature*

Based on the formula for stature reconstruction for American White Females (Trotter 1970), using femoral and tibial length this individual's stature was approximately 165.8 +/- 3.55 cm (65.2 inches). Estimates based on the individual bones were within 1.5 cm of each other.

g) *Population Affinity*

No discriminant functions for distinguishing between populations can be used, and the condition of the skull and the poor condition of the face make assessment of population affinity somewhat difficult. However, the nasal aperture appears to have a slight nasal sill and the zygomatics were apparently retreating rather than projecting. Both of these features are suggestive of a Caucasoid affinity for this individual.

h) *Summary*

This skeleton is the remains of an adult female (in her 30s-40s at the time of death) of European ancestry. Her stature during life was approximately 65.2 inches (5 feet, 5 inches). At the time of death, she had considerable dental disease but no other obvious signs of pathology.

7. FEATURE 38

a) *Skeletal Inventory and Condition*

Only portions of this skeleton are present, and they are quite fragmentary. However, the bone itself is in good condition, i.e., it is not crumbling or eroded.

The occipital, left parietal, petrous portion of the left temporal, left zygomatic, and a portion of the alveolar portion of the maxilla are present. Three maxillary teeth are present (RM^1 and RM^2 and an unidentified left molar).

The mandible is preserved, in excellent condition, though the right side behind the first molar is broken off. Thirteen mandibular teeth are present (LI_1, LI_2, LC, LP_1, LP_2, LM_1 (root), LM_2, RI_1, RI_2, RC, RP_1, RP_2, RM_2). The left third molar was probably present at the time of death and lost postmortem.