c) *Sex*

This individual is certainly female. This is based largely on the characters of the pelvis, especially the pubis. The overall size and gracility of the skeleton are consistent with the diagnosis of female based on the pelvis.

d) *Age*

All epiphyses are fused and this individual was clearly adult. The lack of degenerative arthritis or osteoporosis suggests that the individual was not of an advanced age (probably late 20s through 40s at the time of death), but in the absence of dental remains or a well-preserved pubic symphysis, it is not possible to be more precise.

e) *Cultural Modification*

No cultural modifications were seen on those portions of the skeleton that were preserved.

f) *Stature*

Based on the formula for stature reconstruction for American White Females (Trotter 1970), using humerus length, this individual's stature was approximately 154 cm +/- 4.45 (60.1 inches). Stature reconstruction based on ulna and radius is within the range of the estimate based on the humerus.

g) *Population Affinity*

Because the skull was missing, it was impossible to determine the population affinity of this individual. Nothing from the postcranial skeleton indicated that this individual might not have been of European ancestry, like the other skeletons from this site.

h) *Summary*

This partial skeleton represents an adult female who had no evidence of disease and evidence of only minor degenerative changes such as osteoarthritis. During life she would have been approximately 60.1 inches (5 feet) tall.

4. FEATURE 29

a) *Skeletal Inventory and Condition*

The cranium and mandible were in good condition. Most individual bones of the skull are present (including the right incus [one of the ear ossicles]). Most of the teeth which would have been in the jaws at the time of death were preserved. All four first deciduous incisors are absent, but it is impossible to determine whether they were lost postmortem (likely because they are small, single rooted teeth whose roots had probably already begun to resorb in preparation for being shed) or whether they had fallen out prior to death. The four first permanent molars in which only the crowns and a portion of the roots had formed are present. The crowns of the second permanent molars are visible in the crypts.

The vertebral column is represented by fragmentary vertebral arches which were not fused to the bodies. C1, C2, and two other unidentifiable cervical vertebrae are preserved as well as fragments of at least ten other (thoracic and lumbar) vertebrae. The ribs are also extremely fragmentary. The manubrium and sternum are not preserved in identifiable form.

The innominates and sacrum are preserved in extremely fragmentary form. The innominates are represented only by the portion of the ilium that includes parts of the acetabulum and the sciatic notch.

The lower limbs are represented by a complete right femur, with proximal epiphyses and a fragment of the left femur. The tibiae are represented by portions of the **diaphysis**. The fibulae are not preserved in identifiable form. The feet are preserved only by extremely fragmentary tarsals, metatarsals, and phalanges.

The middle portion of the right clavicle and the region of the right scapula which includes a portion of the scapular spine and glenoid fossa are preserved in very fragmentary condition.

The humeri are preserved in very fragmentary form, with only the right proximal epiphysis present (all other epiphyses are absent). The ulnae and radii are very poorly preserved. Only small fragments of carpals, metacarpals, and hand phalanges are present.

b) *General Description and Pathology*

1) Cranium

All bones of the skull are present; however, because of the age of the individual, they had not yet fused together at the time of death. All of the bones are smooth and thin as is characteristic of juveniles. Both the right and left orbits have porous, reactive bone on the surface of the roof (**cribra orbitalia** or porotic hyperostosis), with some areas being extremely porous and others being characterized by "worm tracks" (see Plate 31). The frontal has an area of "microporosity" in the region around glabella. In addition, there is similarly mild porosity on the occipital in the region of inion. Both cribra orbitalia and porosity of cranial bone are suggestive of nutritional stress such as anemia.

The maxilla has the entire **deciduous dentition** with the exception of the right and left dI^1 (see Plate 32). The first permanent incisors are visible in the crypts. The first permanent molars are present in the maxillary alveolus with the beginnings of root formation. Similarly, the mandible has the entire deciduous dentition with the exception of the right and left dI_2 (see Plate 33). Again, it is possible that these were lost postmortem, but in this case, the first permanent molars had already broken through the alveolus at the time of death (though they were not close to being in occlusion). The first permanent molars are in the mandible, but have not erupted to the occlusal level.

No dental caries or other dental pathology are visible on the deciduous dentition or the permanent dentition which had erupted through the alveolus at the time of death.

The postcranial skeleton is extremely fragmentary. In most cases measurement is impossible. No pathology of any sort was visible on the portions of postcrania which could be observed.

2) Vertebral Column

In all cases, the vertebral arches are not fused to the vertebral bodies as would be expected in a child of this age. Fragmentary condition of these bones precludes further description.

3) Sacrum and Pelvis

Like the rest of the vertebral column, the sacral body is not fused to the arch. The right and left portions of the ilium are not fused to the pubis or ischium.

PLATE 31: The Frontal of the Individual from Feature 29 in Anterior-Inferior View.
This photograph was taken looking up into the tops of the orbits in order to show the cribra orbitalia (porous bone and "worm tracks) on the orbital roofs.

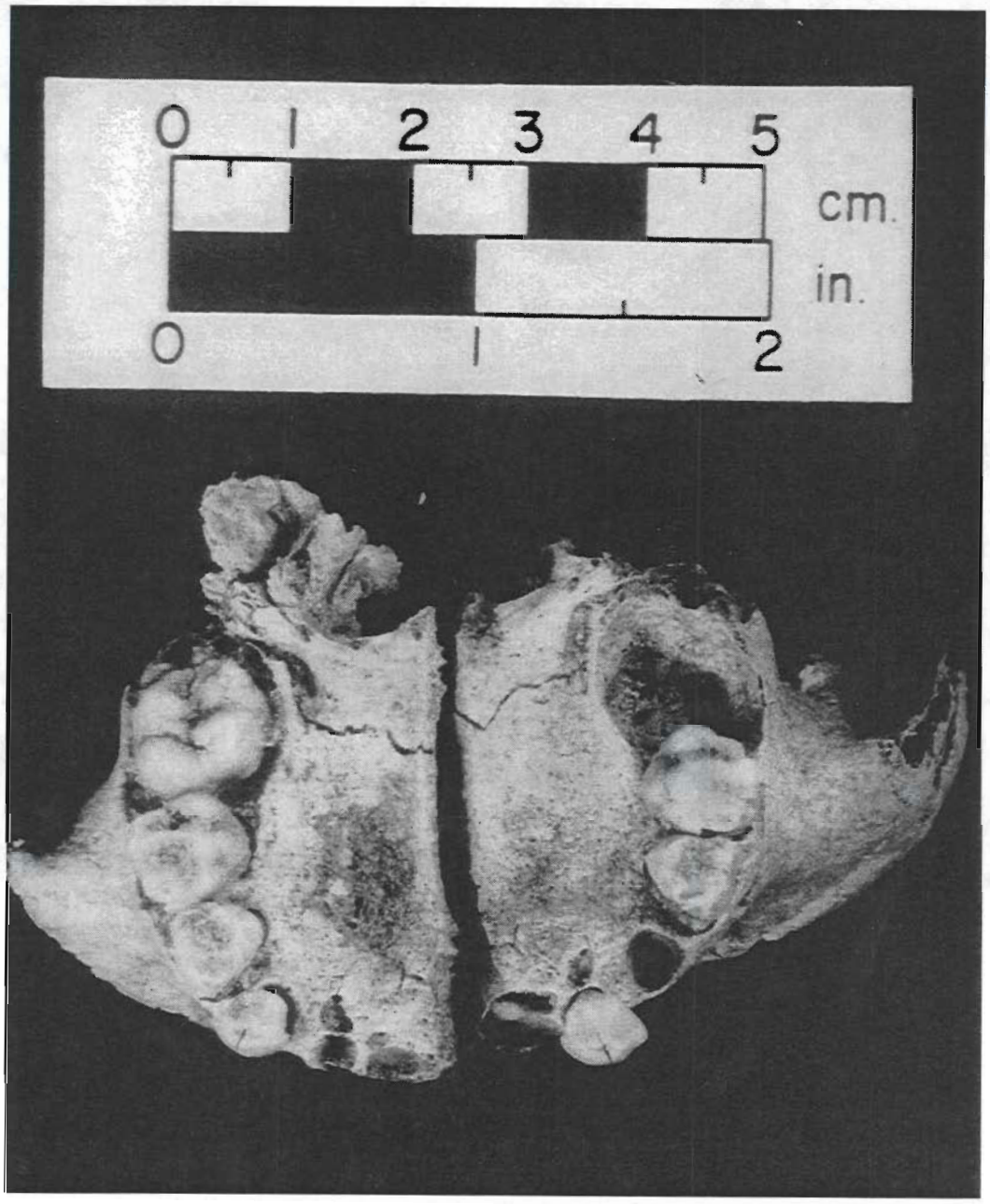

PLATE 32: The Maxillae from the Individual from Feature 29 in Occlusal (Inferior) View.

Anterior (towards the front of the individual) is at the bottom of the photograph. The two sides of the maxilla are unfused and the teeth shown in this picture are mostly from the deciduous dentition. On the left of the photograph, the tooth at the back of the jaw is the first permanent molar. The first permanent incisor is visible in the crypt at the front of the jaw on the right. Not all teeth which were present in the laboratory have been included in this photograph

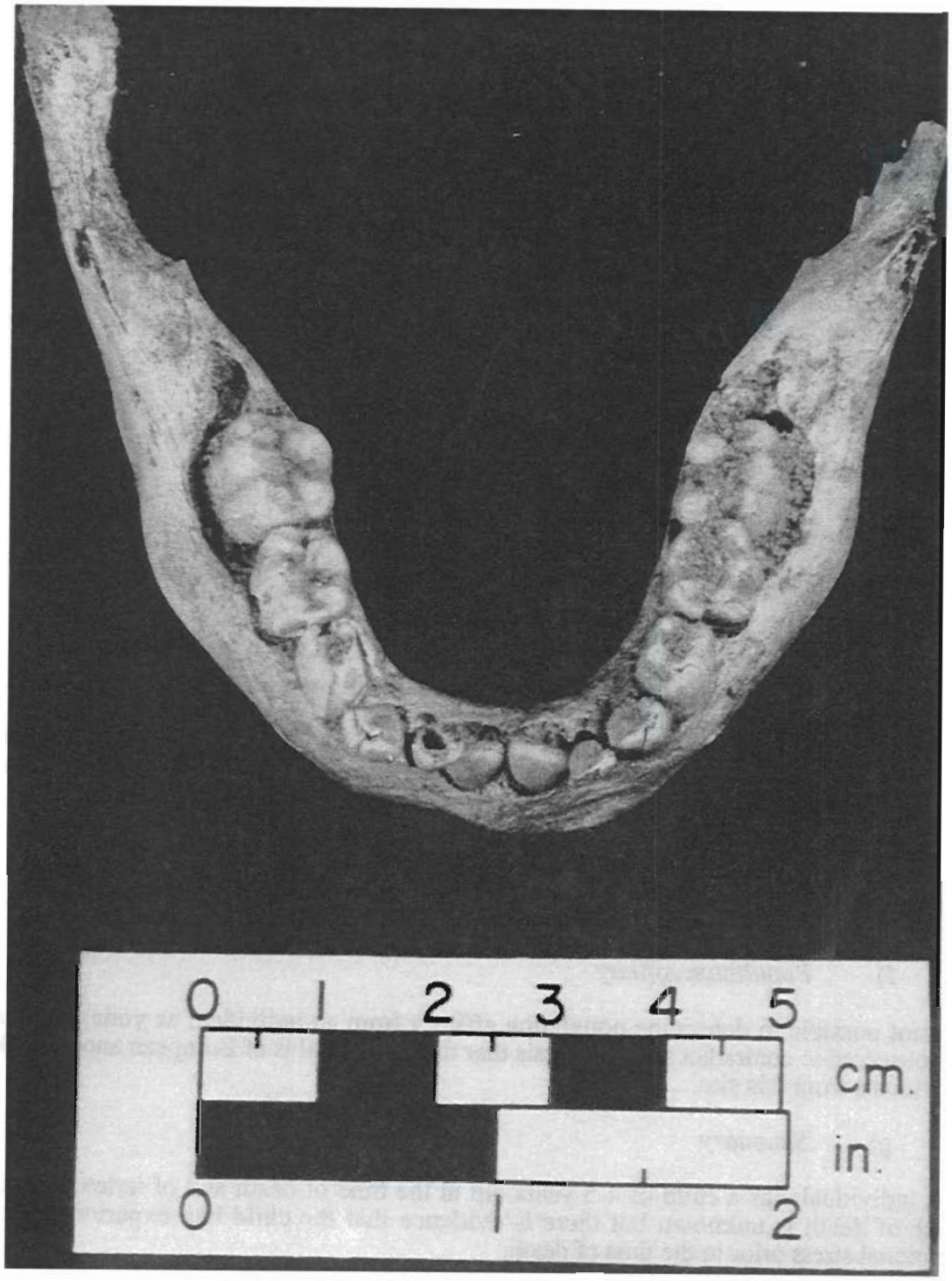

PLATE 33: The Mandible from the Individual from Feature 29 in Occlusal (Superior) View.

The most posterior teeth on each side are the first permanent molars which were just erupting at the time when this child died. The permanent incisors are visible in the crypt at the bottom of the photograph (in the front of the jaw).

4) Ribs, Manubrium, and Sternum

These bones are so fragmentary that no description or observation is possible.

5) Lower Limb

The femoral diaphyseal shaft is 201 mm long (this should be considered a minimum, given the somewhat eroded condition of the diaphyseal ends). This is within the range of femoral diaphyseal lengths reported by Ubelaker (1978: Figure 66) for subadults from a number of human samples of the same age as this individual.

6) Upper Limb

The bones of the upper limb are too fragmentary for measurement.

c) *Sex*

It is not possible to determine the sex of an individual of such a young age.

d) *Age*

The formation and eruption of the dentition fits a stage between 4 +/- 1 year and 5+/- 1.5 years on dental formation and eruption standards in Ubelaker (1978). The first molars have some root formation (to the point where the roots start to diverge) and the deciduous dentition has not been lost (with the possible exception of the central incisors). The stage of epiphyseal fusion is consistent with this age estimate as is the length of the femoral diaphyseal shaft.

e) *Cultural Modification*

No cultural modifications of the bone were seen on this individual's skeleton.

f) *Population Affinity*

It is not possible to determine population affinity from an individual as young as this. Nothing was observed to contradict the hypothesis that this individual is of European ancestry like the other individuals from this site.

g) *Summary*

This individual was a child of 4-5 years old at the time of death and of indeterminate sex. The cause of death is unknown but there is evidence that the child had experienced some sort of nutritional stress prior to the time of death.

5. FEATURE 30

a) *Skeletal Inventory and Condition*

The skull and mandible are complete and in very good condition for an infant. The right parietal, right frontal, petrous portions of both temporal bones, occipital, right zygomatic bone, and both sides of the mandible are present. The crowns of two upper central deciduous incisors are present. The crowns of the two lower central deciduous incisors are visible in the mandible.